# 重度牙周炎患者即刻种植即刻修复病例一例

南方医科大学口腔医院种植中心　赖春花博士

刘xx，男，48岁

主诉：全口多颗牙松动数年，要求种植修复

现病史：患者数年前开始出现全口多颗牙松动，咀嚼无力，牙龈出血，3年前曾在外院行牙周治疗，自觉治疗效果不理想，未能坚持治疗。现觉牙齿松动进一步加剧，要求拔除后种植修复。

既往史：否认系统性疾病史，否认药物过敏史

**检查：**

**颌面部左右对称，比例协调，上下唇丰满度佳，张口度约为三横指，下颌张口无偏斜，颞下颌关节无弹响。**

## 检查：

口腔卫生较差。
14-17 / 25-27 / 37 / 47缺失。
余留牙牙龈红肿明显，较多菌斑牙结石堆积，PD：3-8mm，BOP（+）。
11 / 22 / 23 / 36 / 33-44松动III度；12 / 21 / 24 / 34 / 35 / 45松II度；13 / 46松I度
上前牙向唇侧扇形移位，垂直距离降低。

# X线检查

[ 2016-8-31 ,16:11:16
Sirona ORTHOPHOS
53%
7月,M,P197143
DX20160831041
SIDEXIS Study
B
6084 >
3 厘

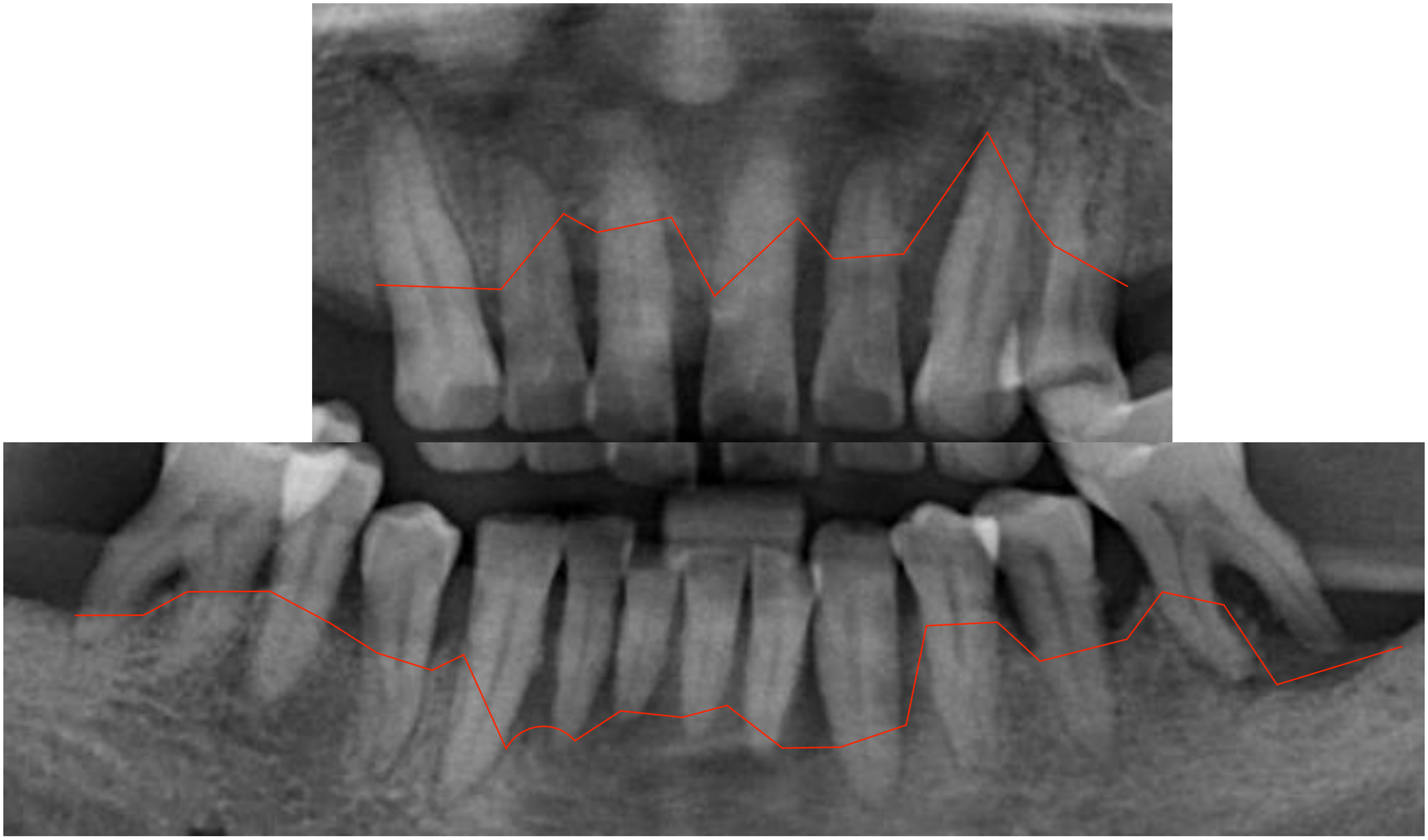

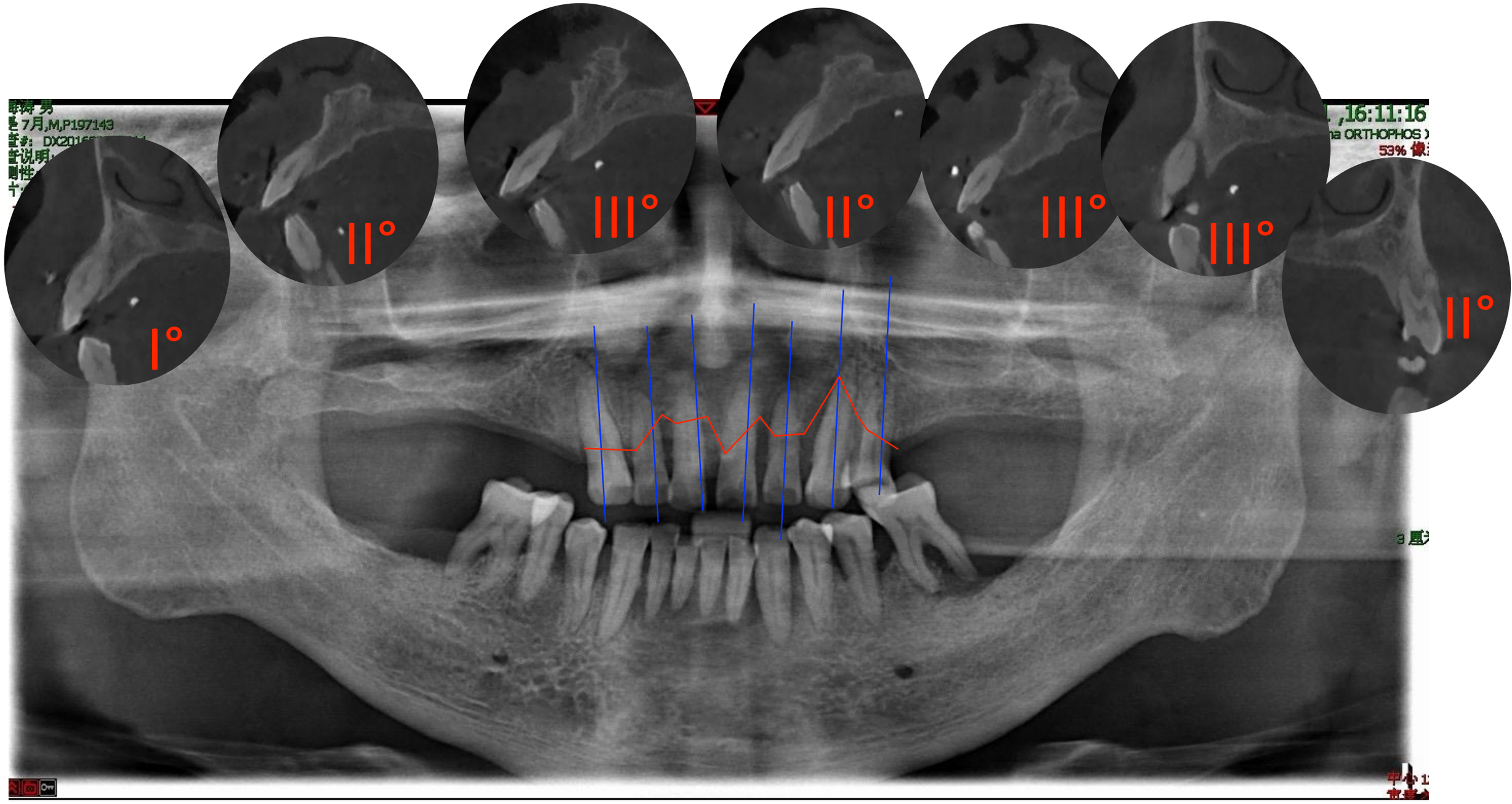
I°
II°
III°
II°
III°
III°
II°

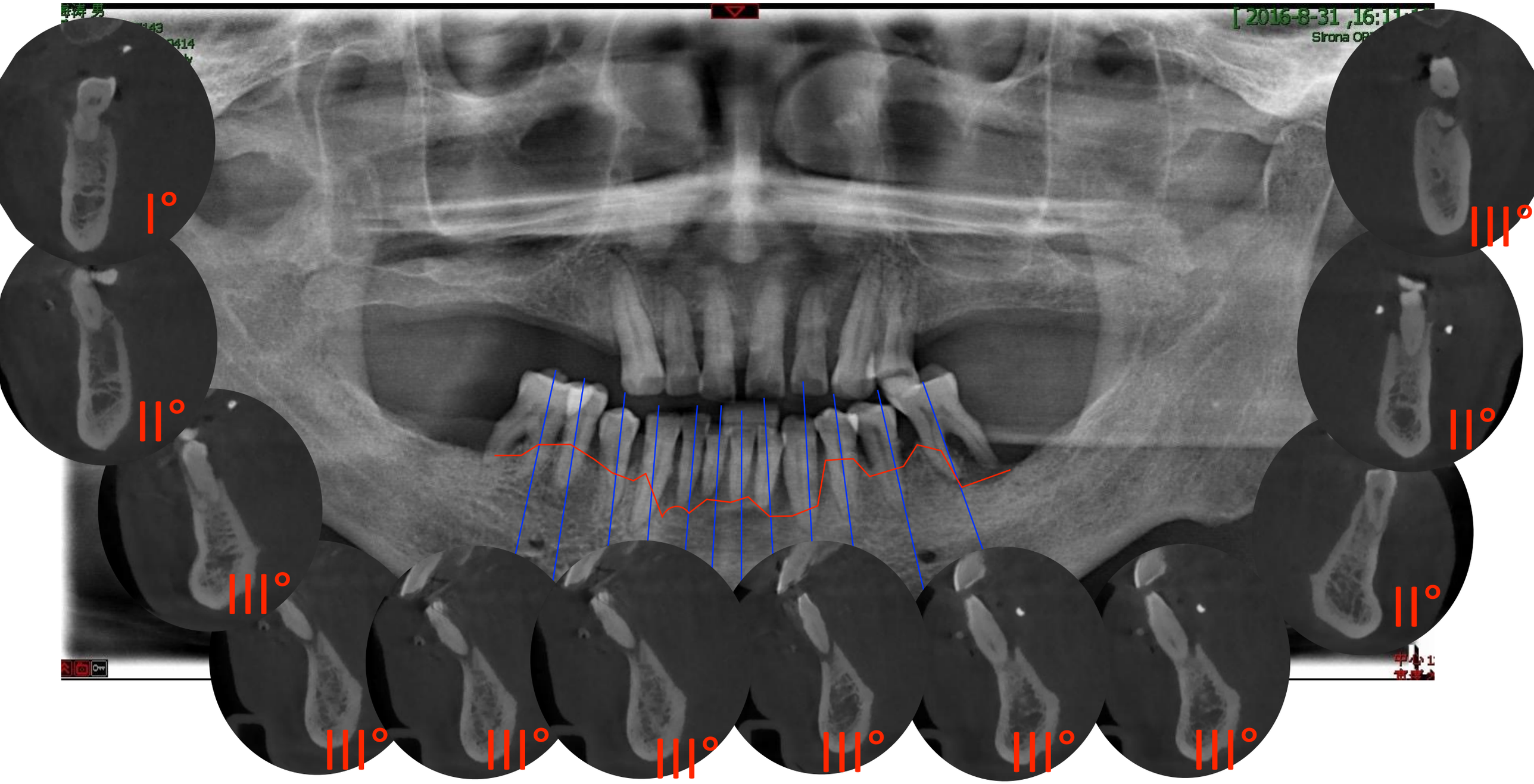
I°
III°
II°
II°
III°
II°
III°
III°
III°
III°
III°
III°

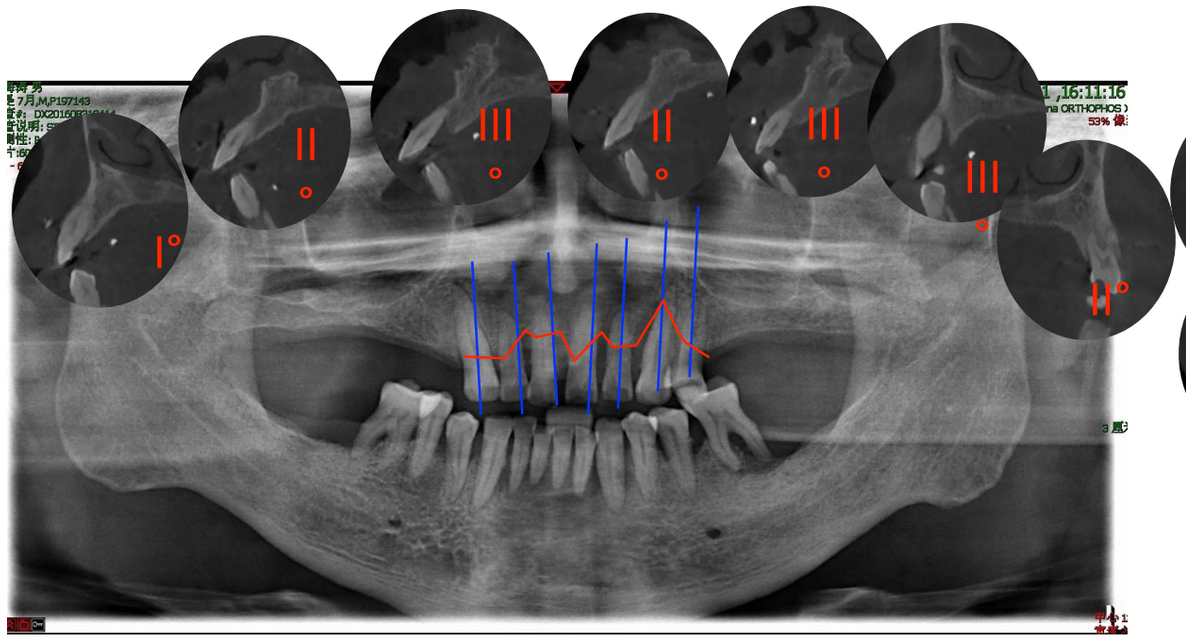


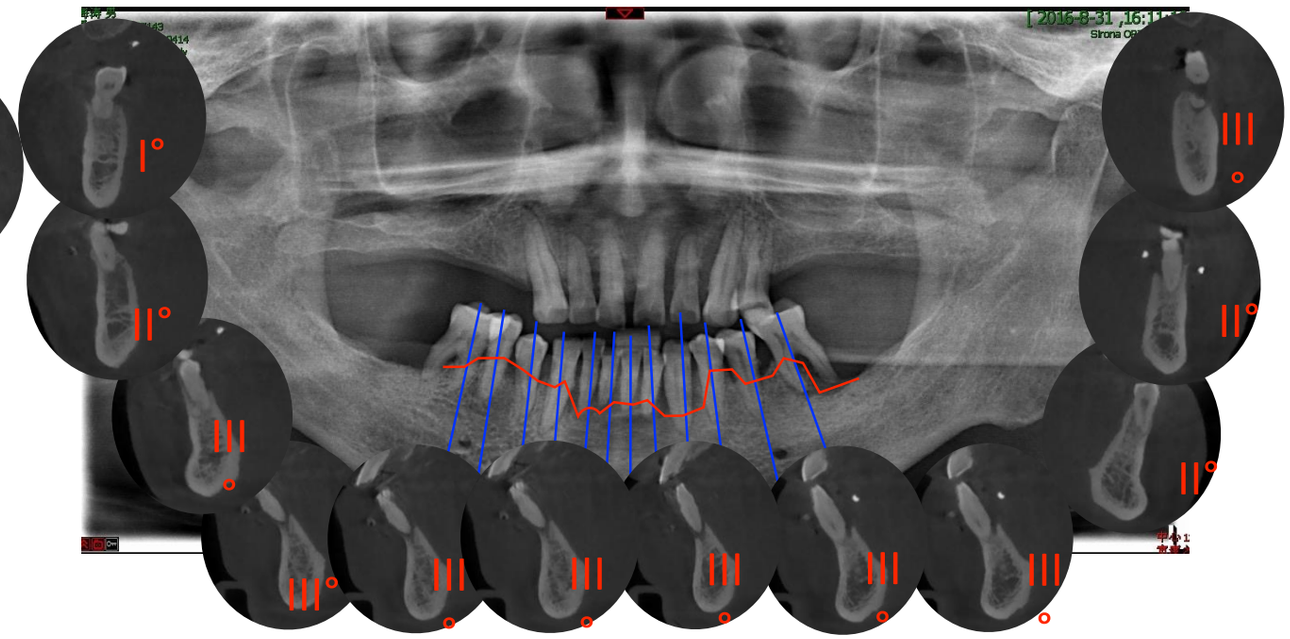


**诊断：**

**1.牙列缺损**

**2.重度牙周炎**

**治疗计划：**

**拔除余留牙，种植修复**

# 能否即刻种植即刻修复?

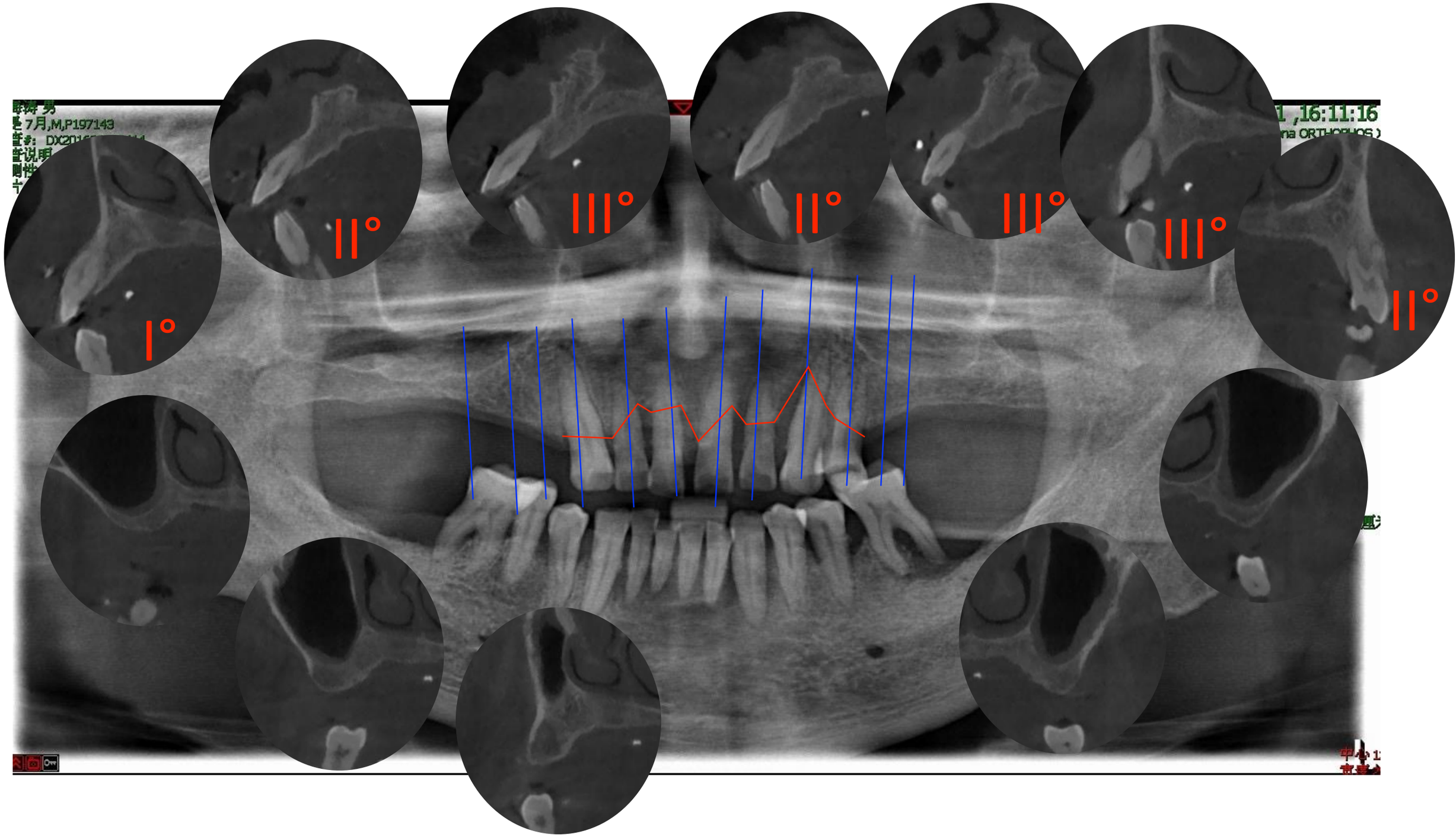
I°
II°
III°
II°
III°
III°
II°

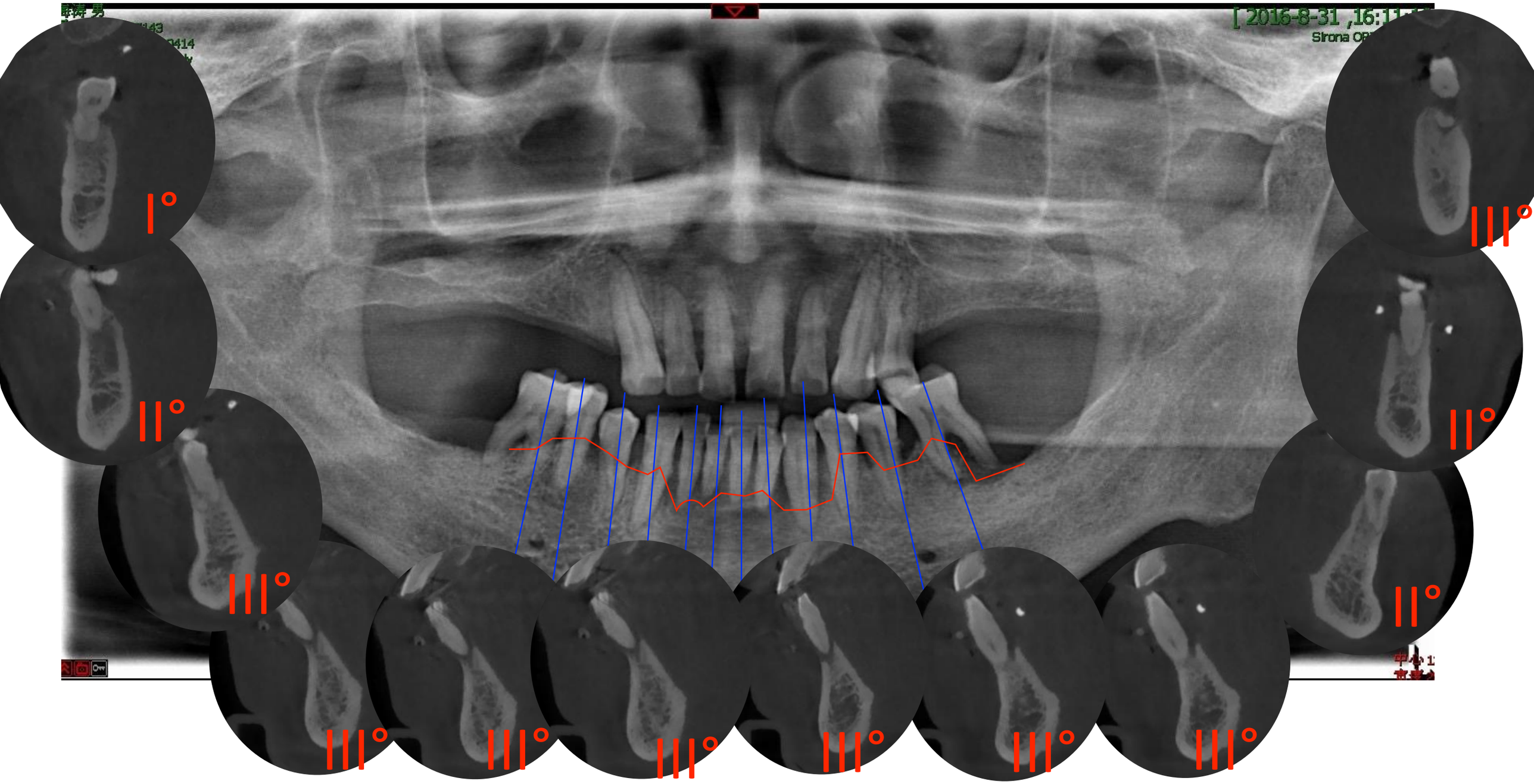
I°
II°
III°
III°
III°
III°
III°
III°
III°
II°
II°

**充分利用剩余骨量 + 适当的植骨**

**即刻种植即刻修复**

# 治疗过程（咬合处理）：

取模上颌架

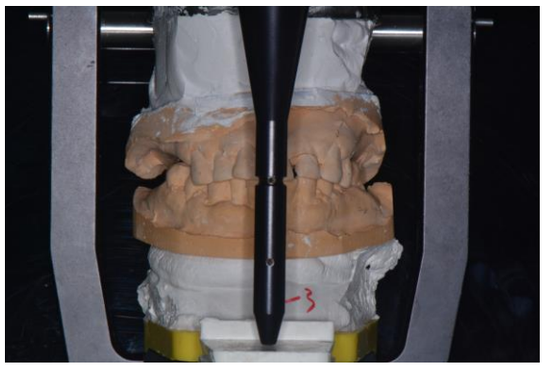

颌架上升高咬合

磨除余留牙

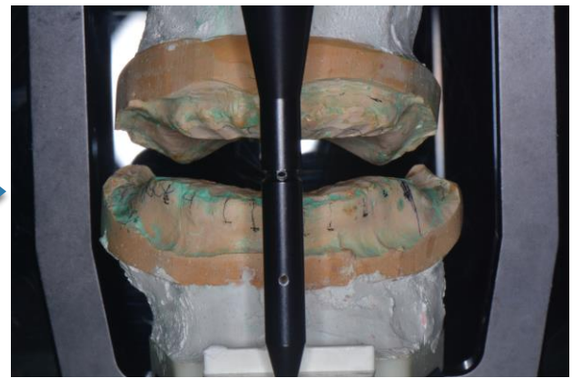

排蜡牙

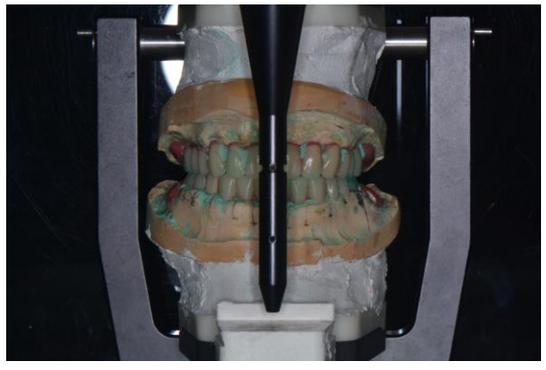

取模用的个别托盘

# 治疗过程（数字化导板设计）

口腔卫生宣教 → 龈上洁治 → 口内固定松动牙

取模上颌架

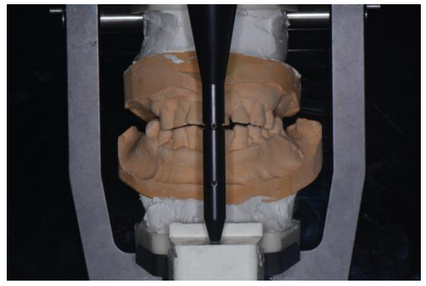

磨除余留牙

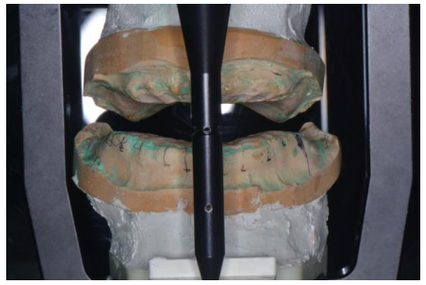

排蜡牙

导板设计

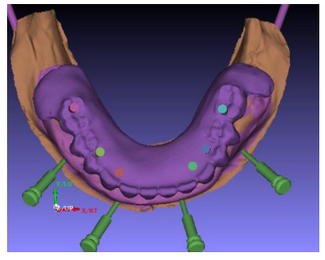

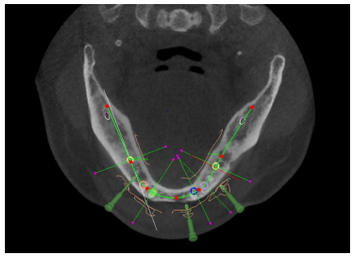

制备放射导板

戴导板
CBCT检查

DICOM数据

# 上颌种植位点的选择：

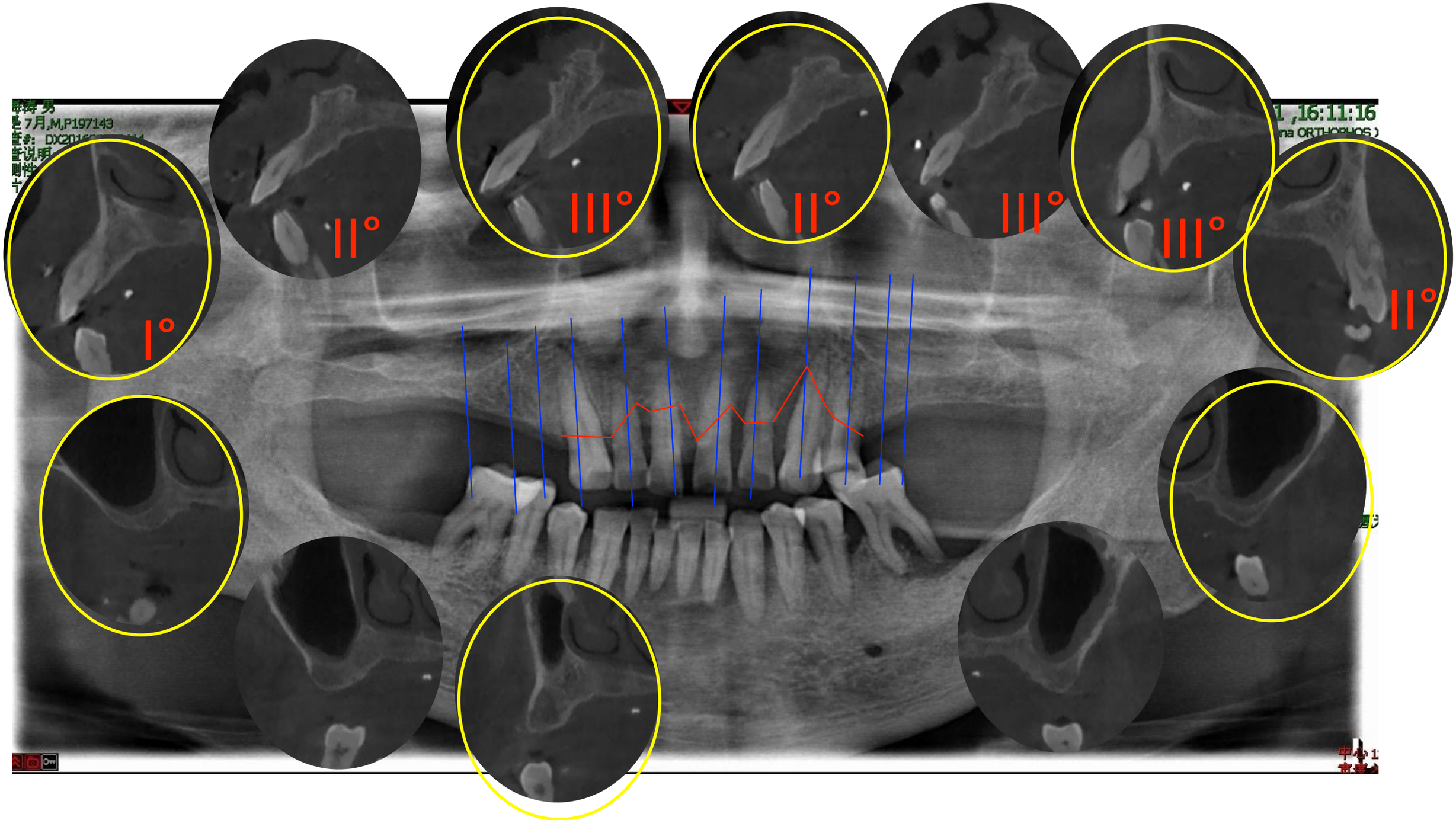


上颌植入位点16，14，13，11，21，23，24，26

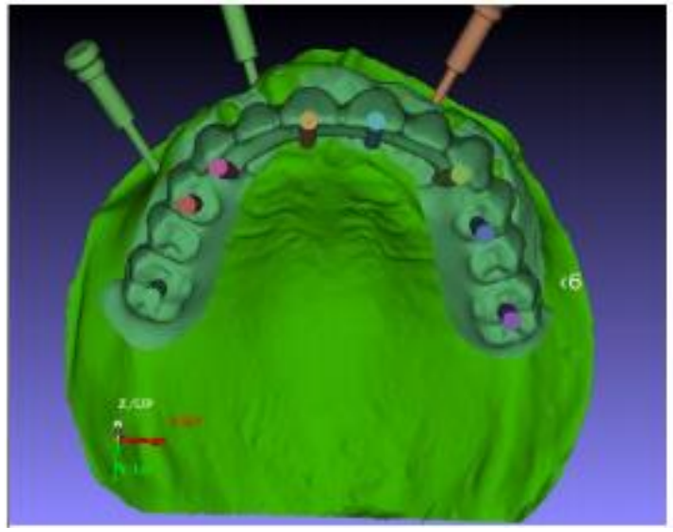

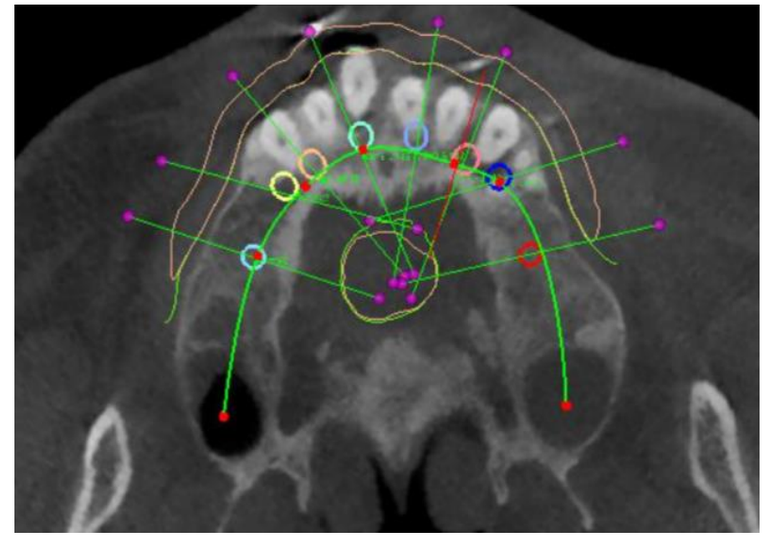

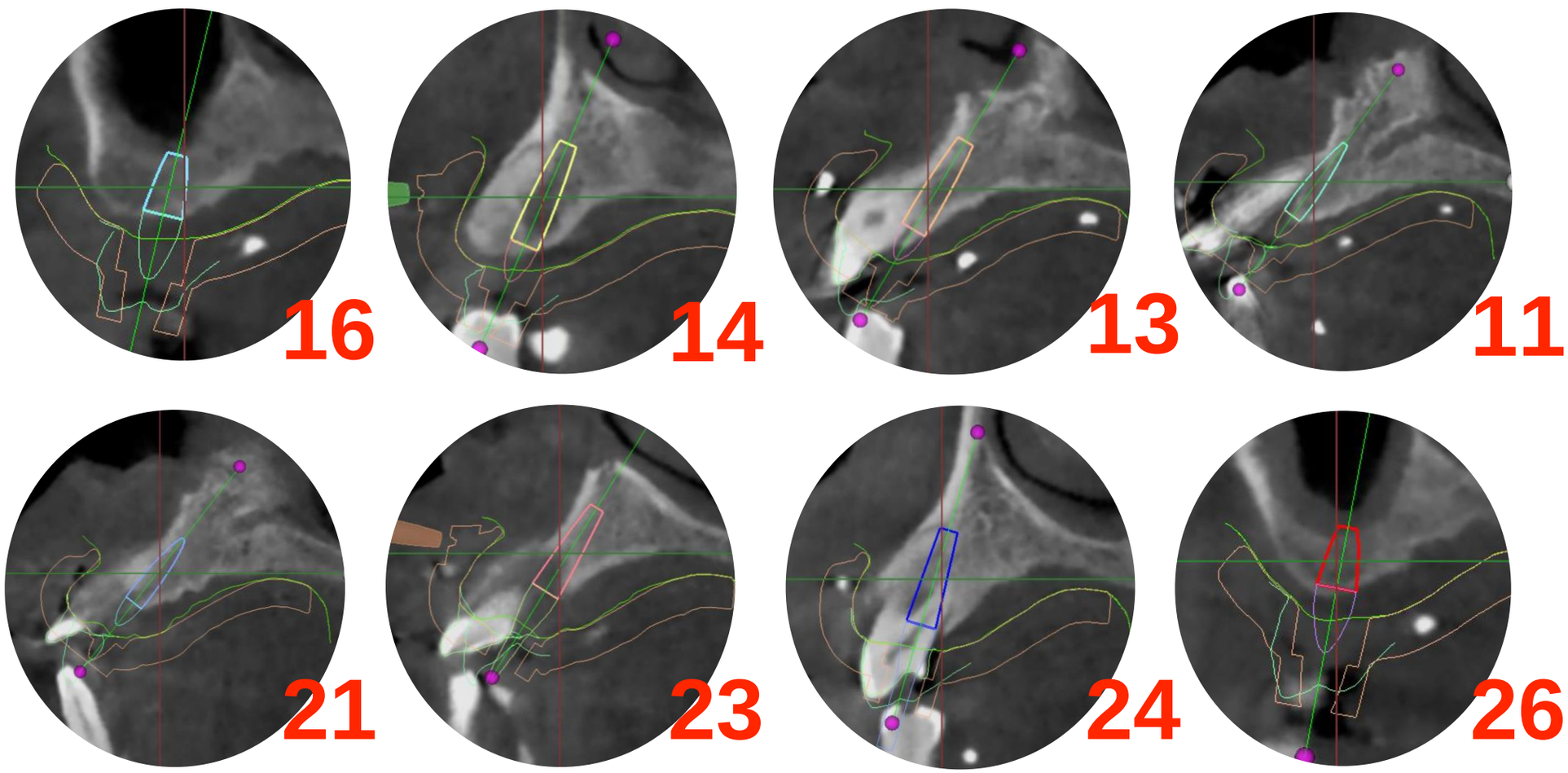


**上颌植入位点16，14，13，11，21，23，24，26**

# 下颌位点设计：种植位点的选择

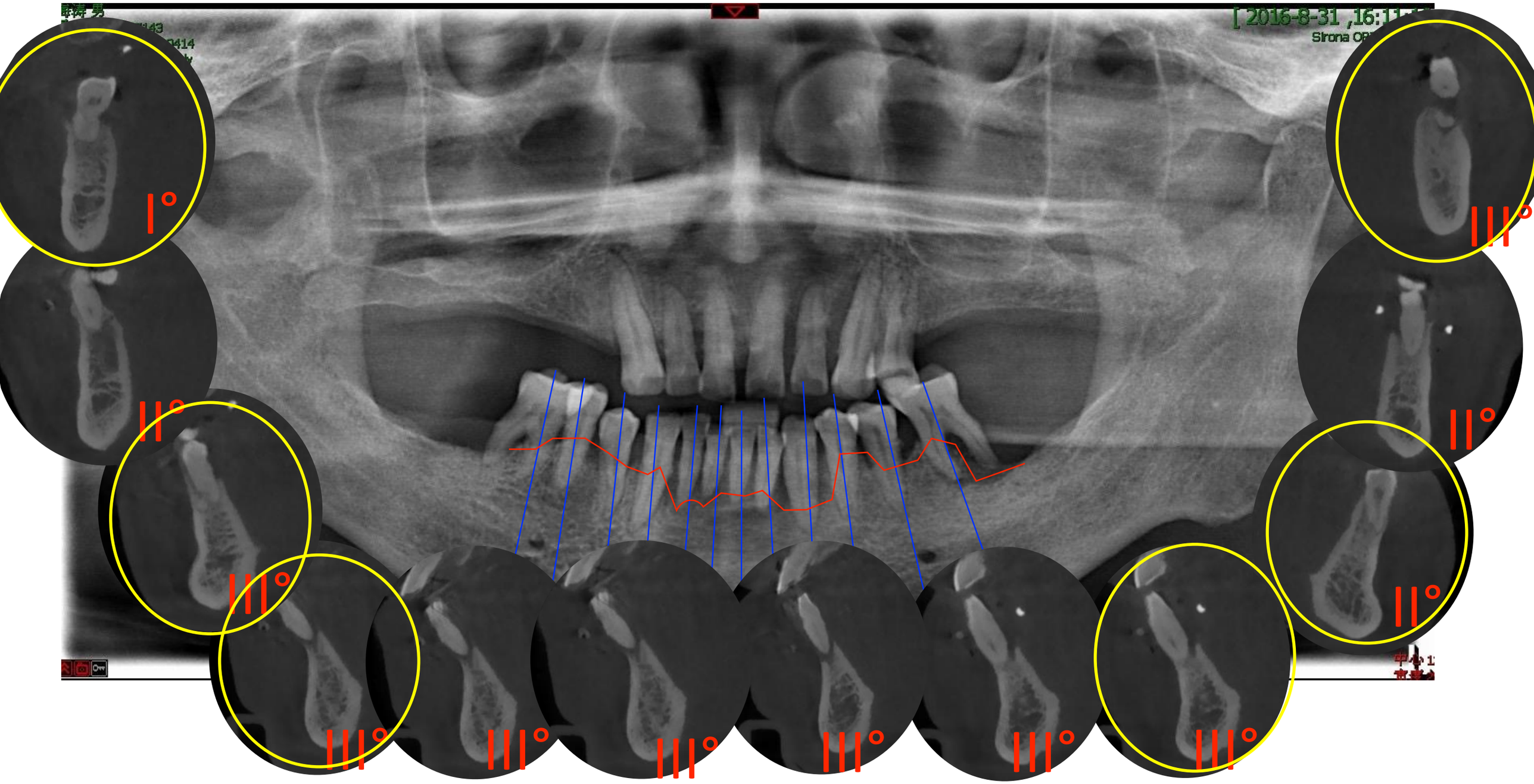

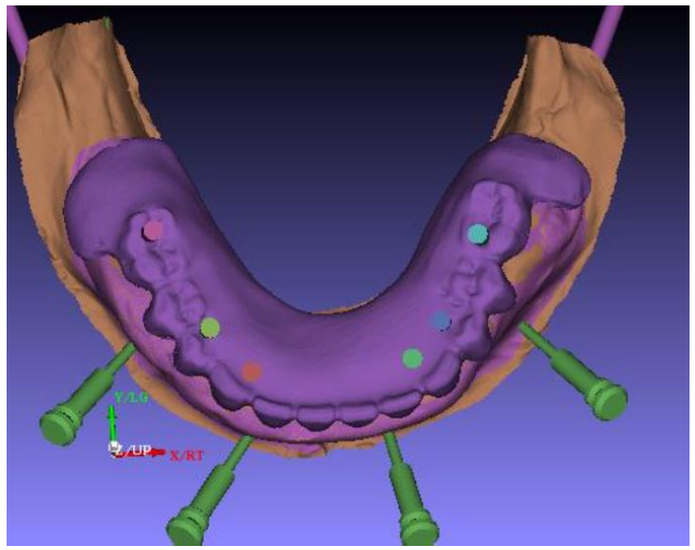


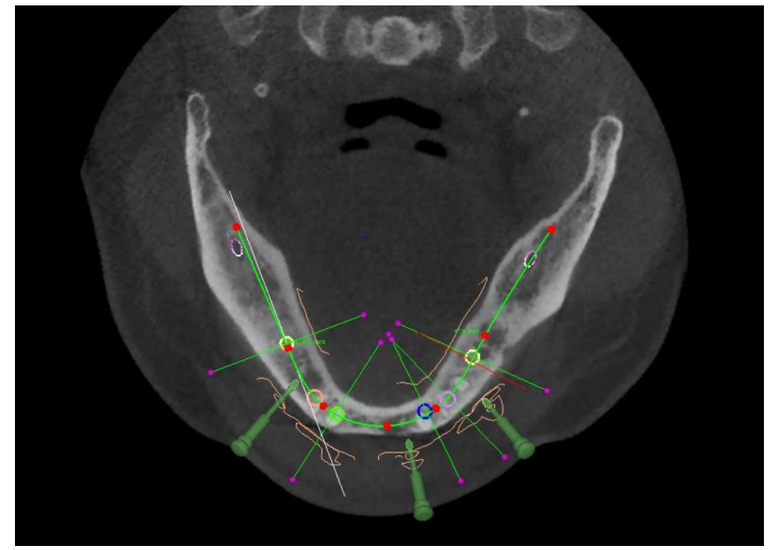

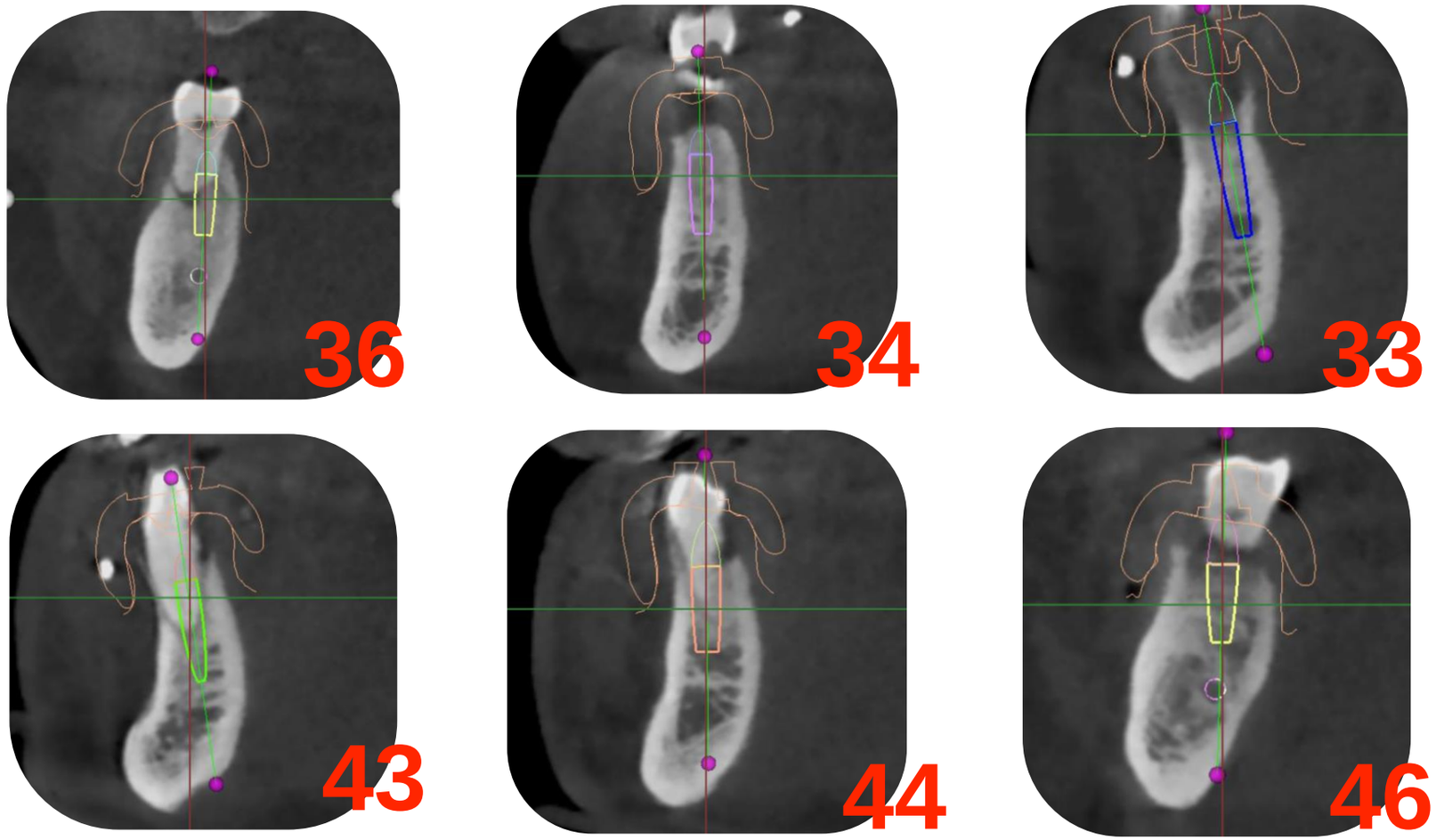


**下颌植入位点36，34，33，43，44，46**

# 一期手术

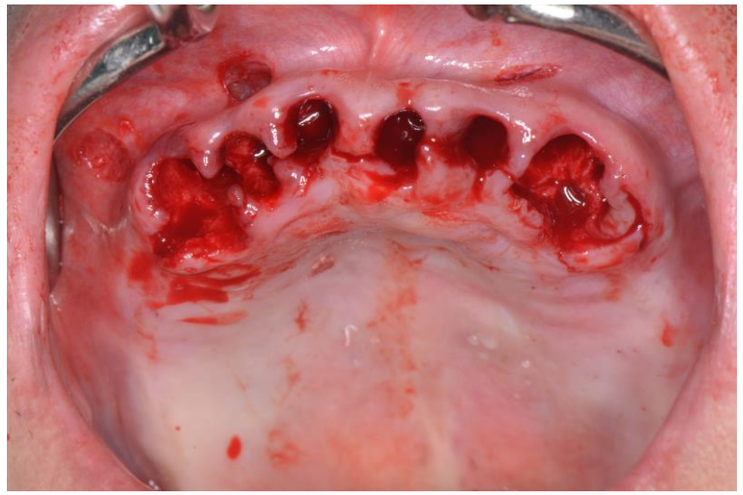

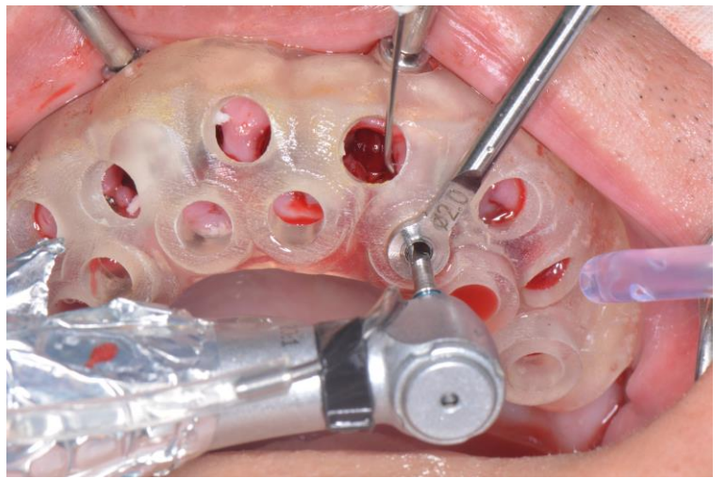

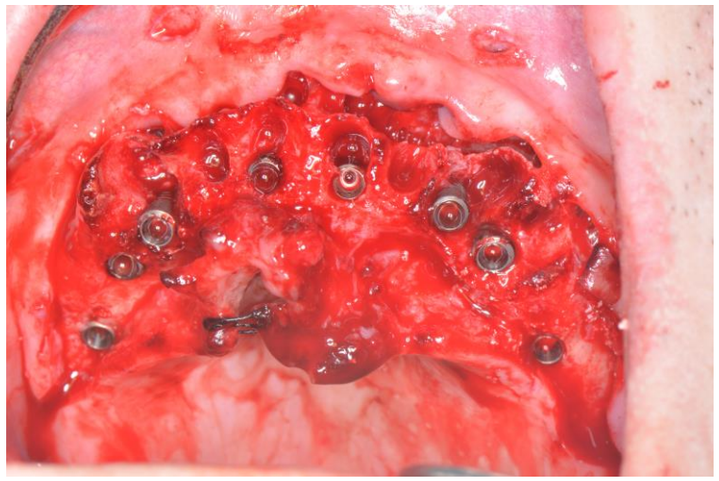

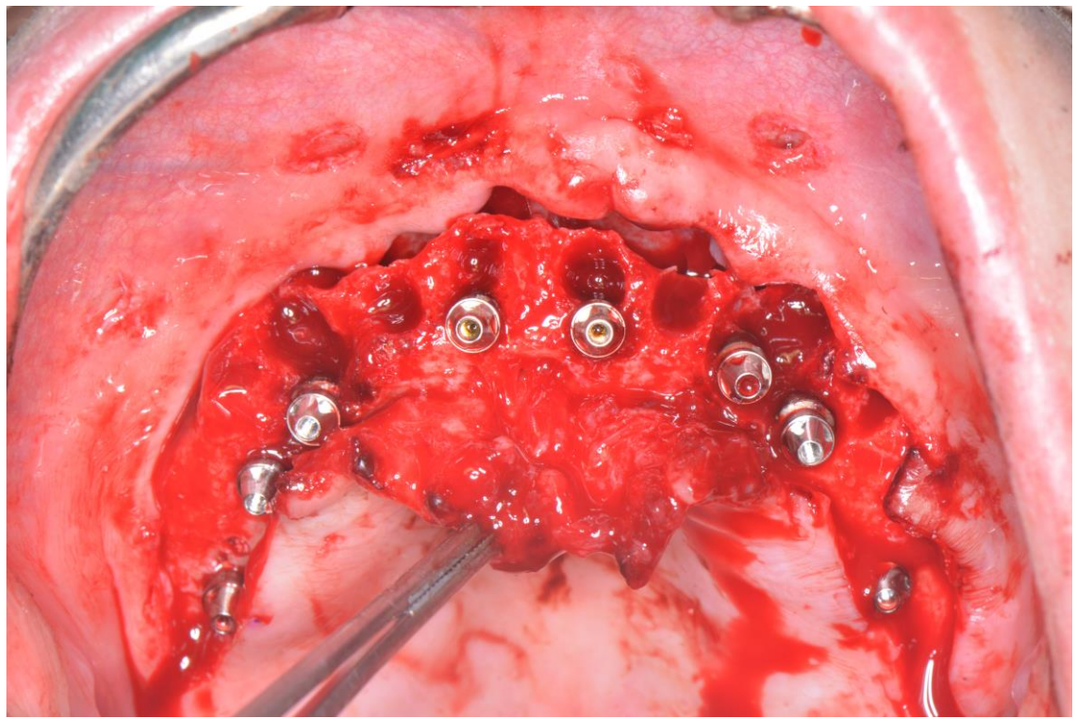

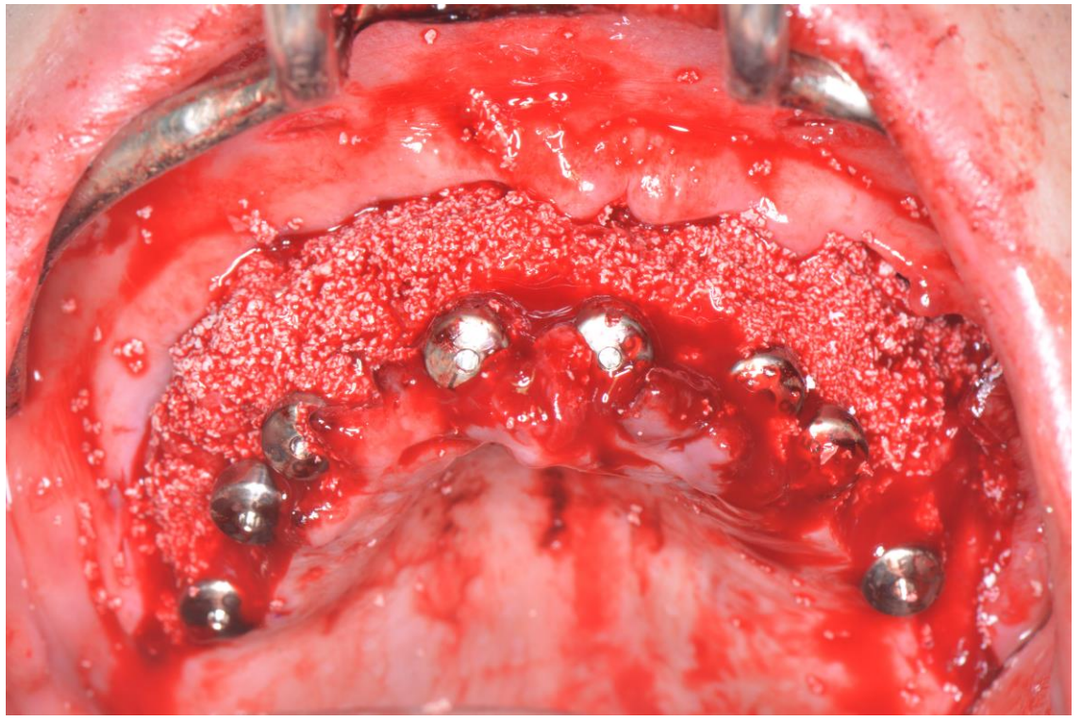

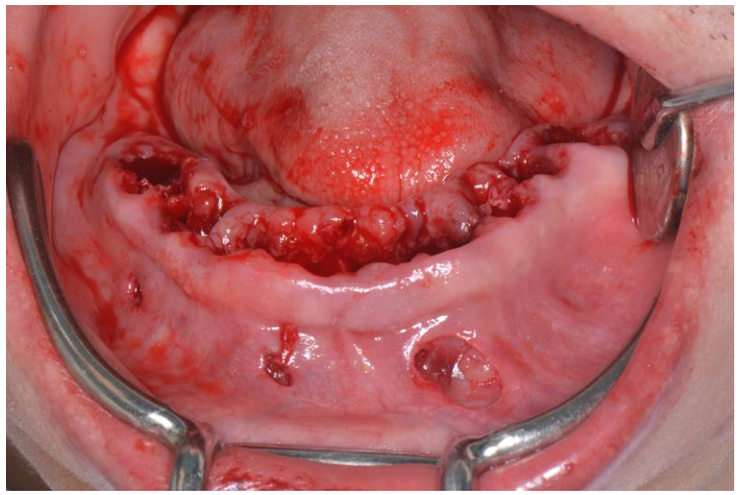
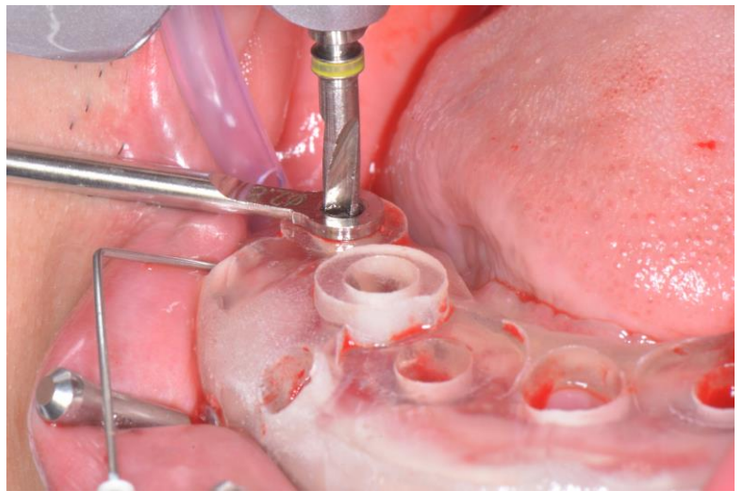
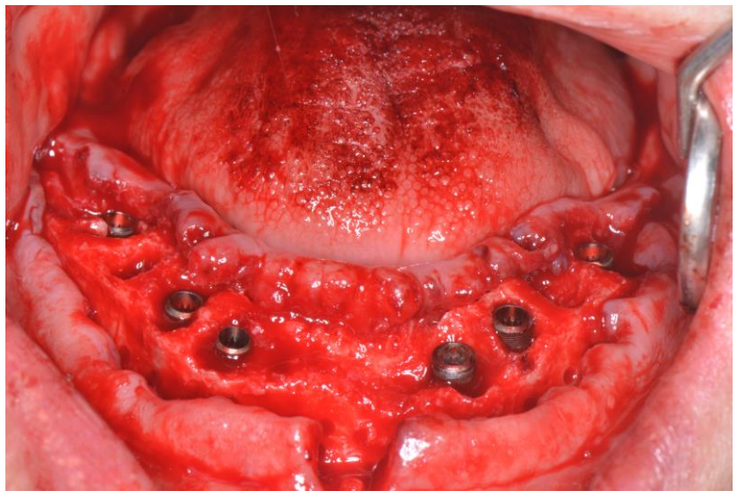

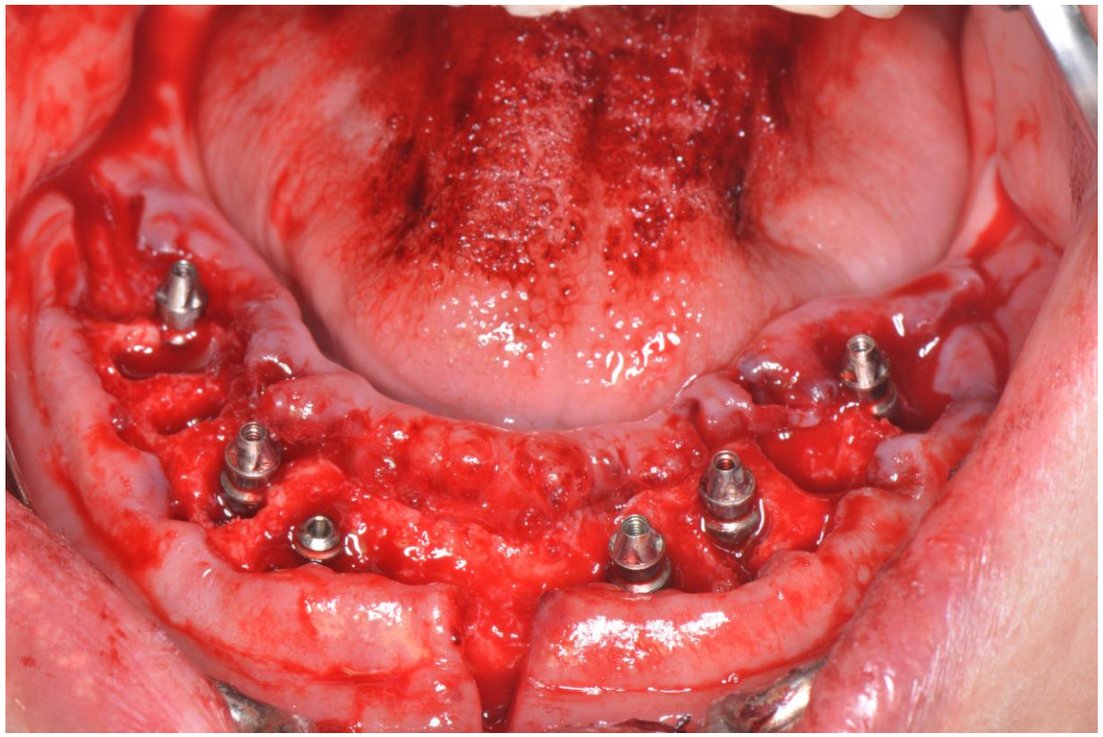

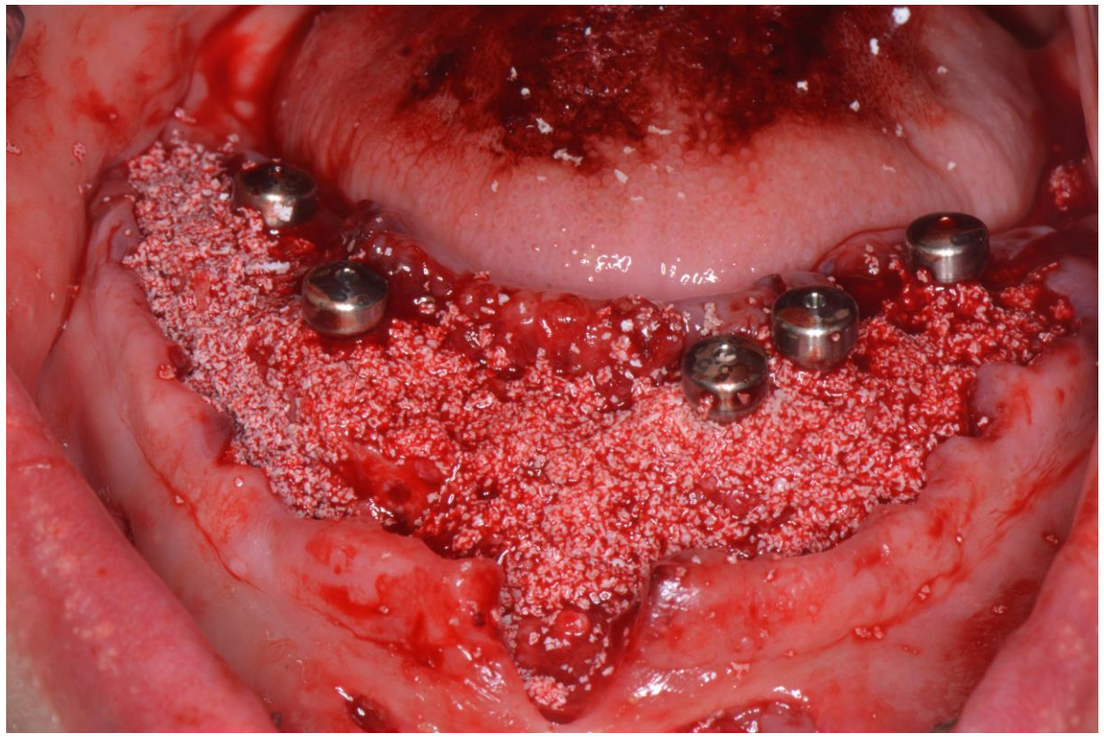

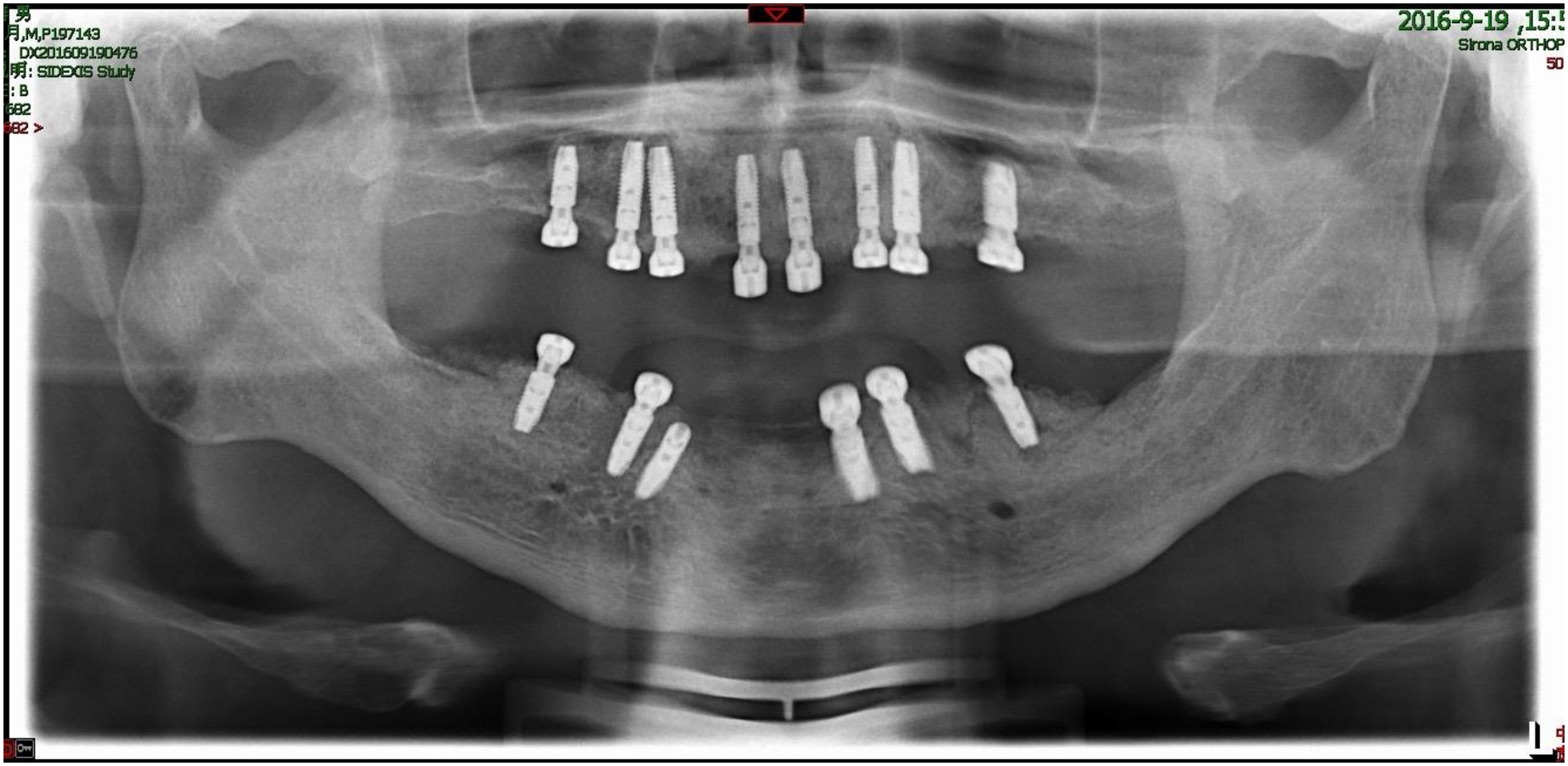
男
月,M,P197143
DX201609190476
明: SIDEXIS Study
: B
682
682 >
2016-9-19 ,15:5
Sirona ORTHOP
50

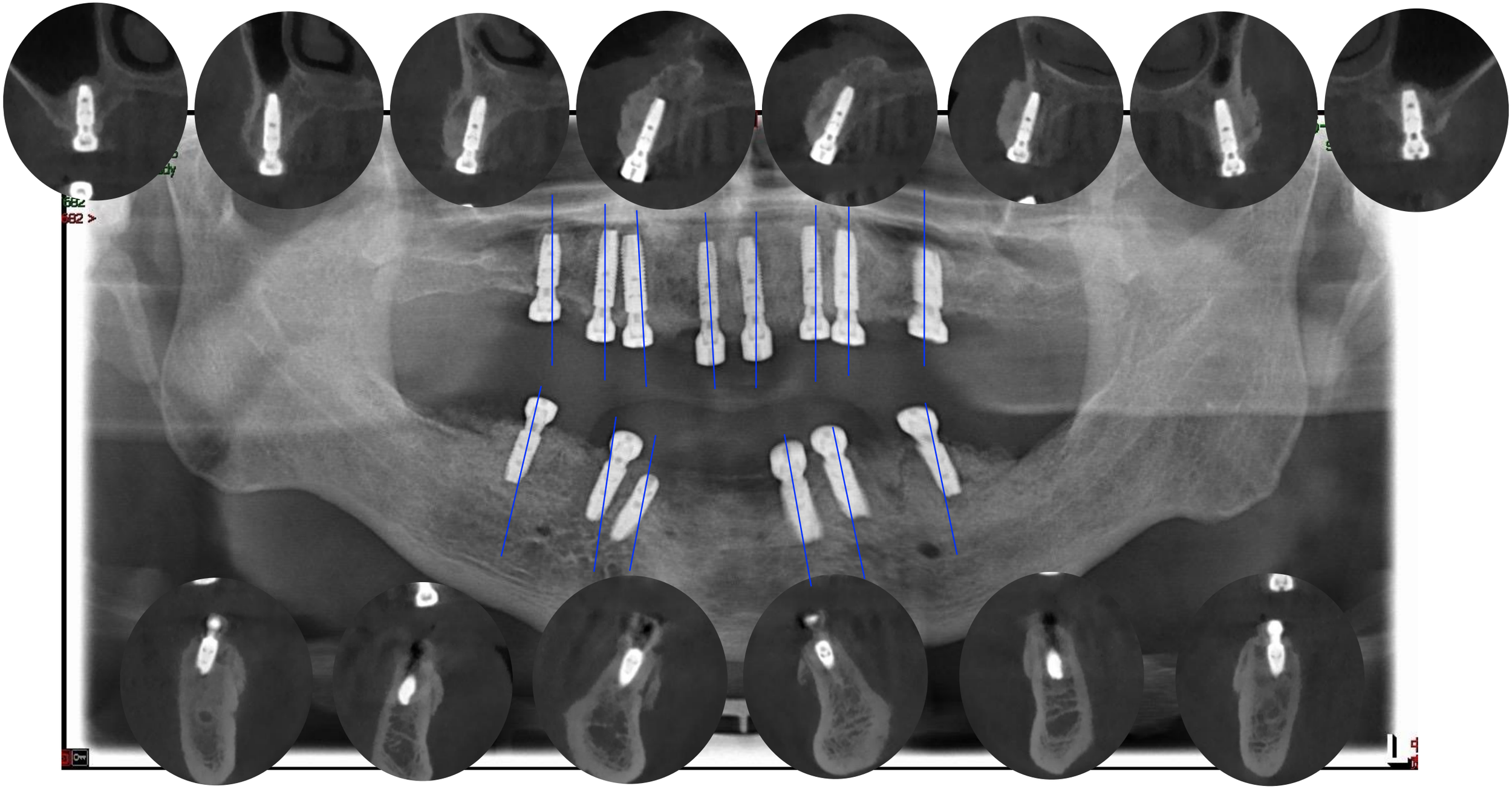

# 植体理想的三维位点

# 植体周围充足的骨量

# 术后当天转移

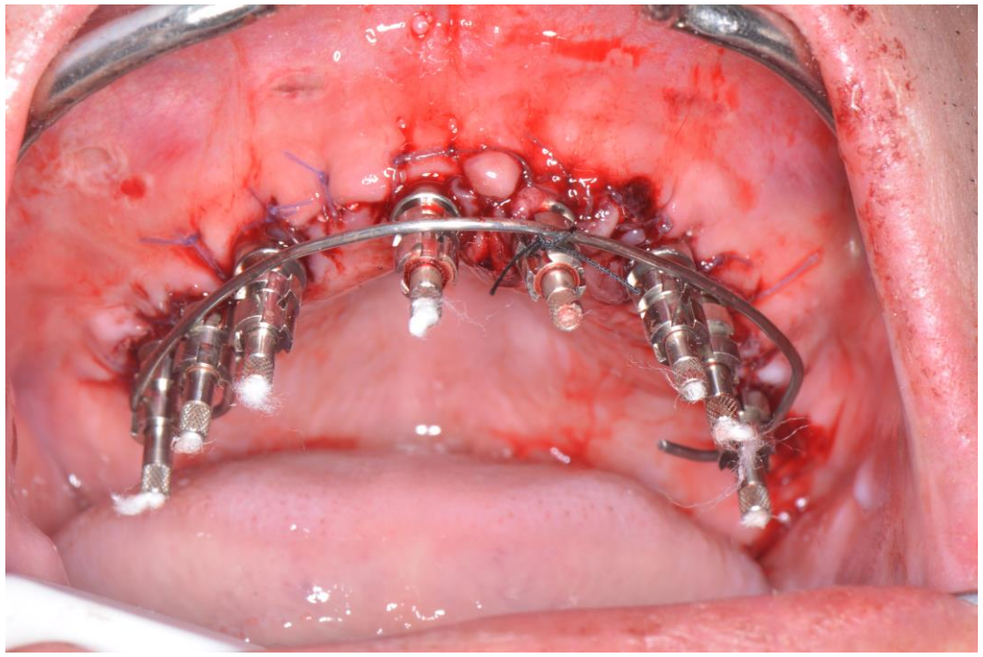

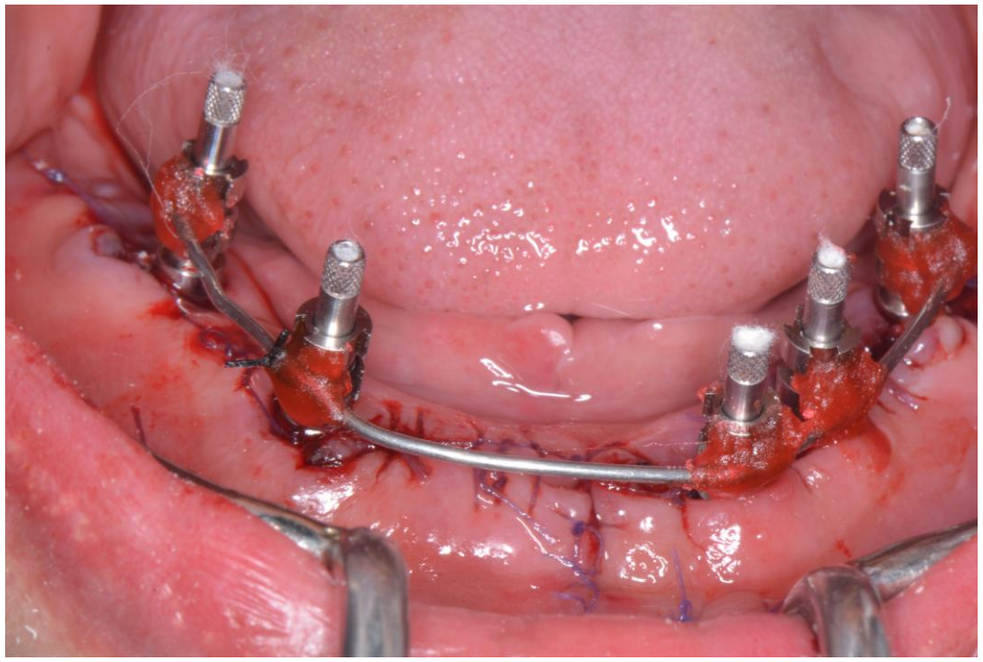

# 转移（咬合处理）：

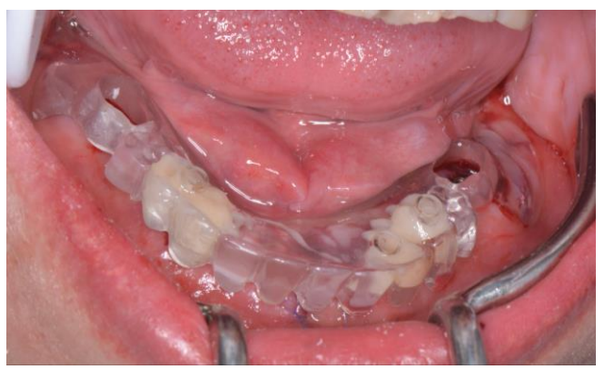

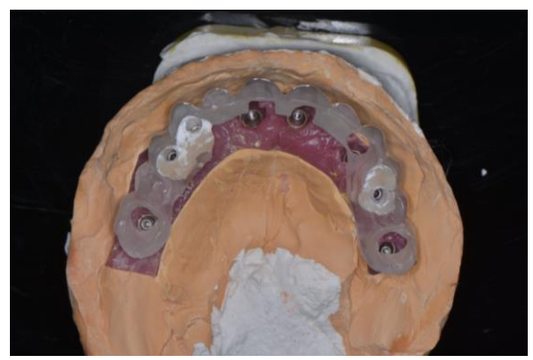

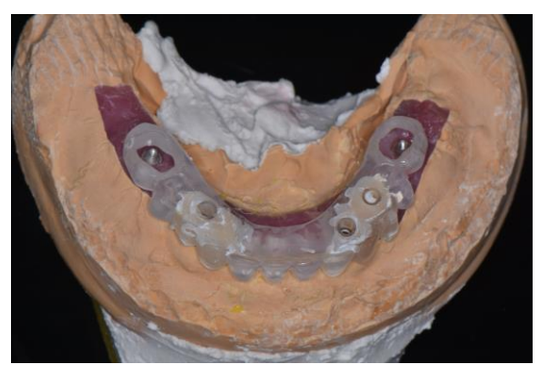

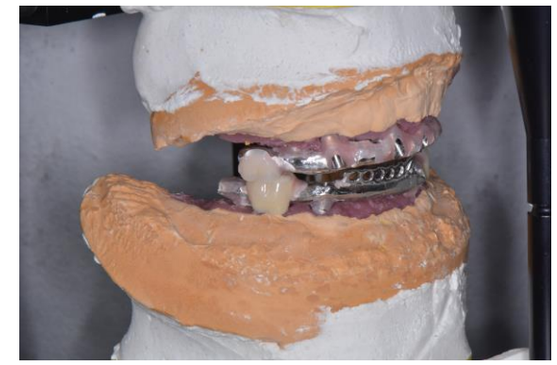

# 一周后戴牙

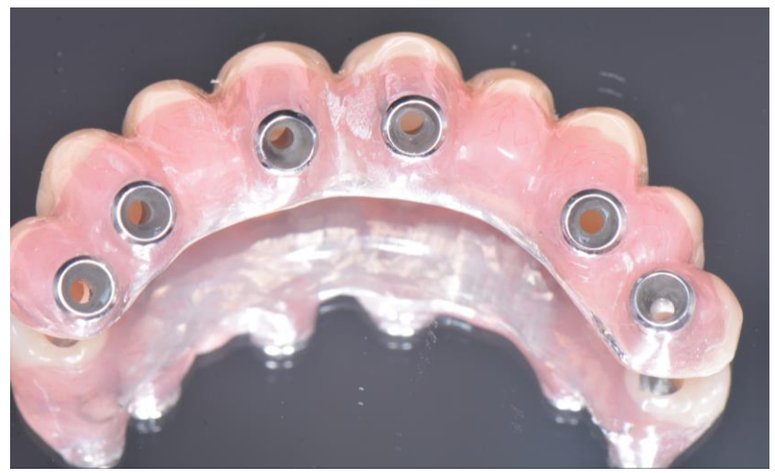

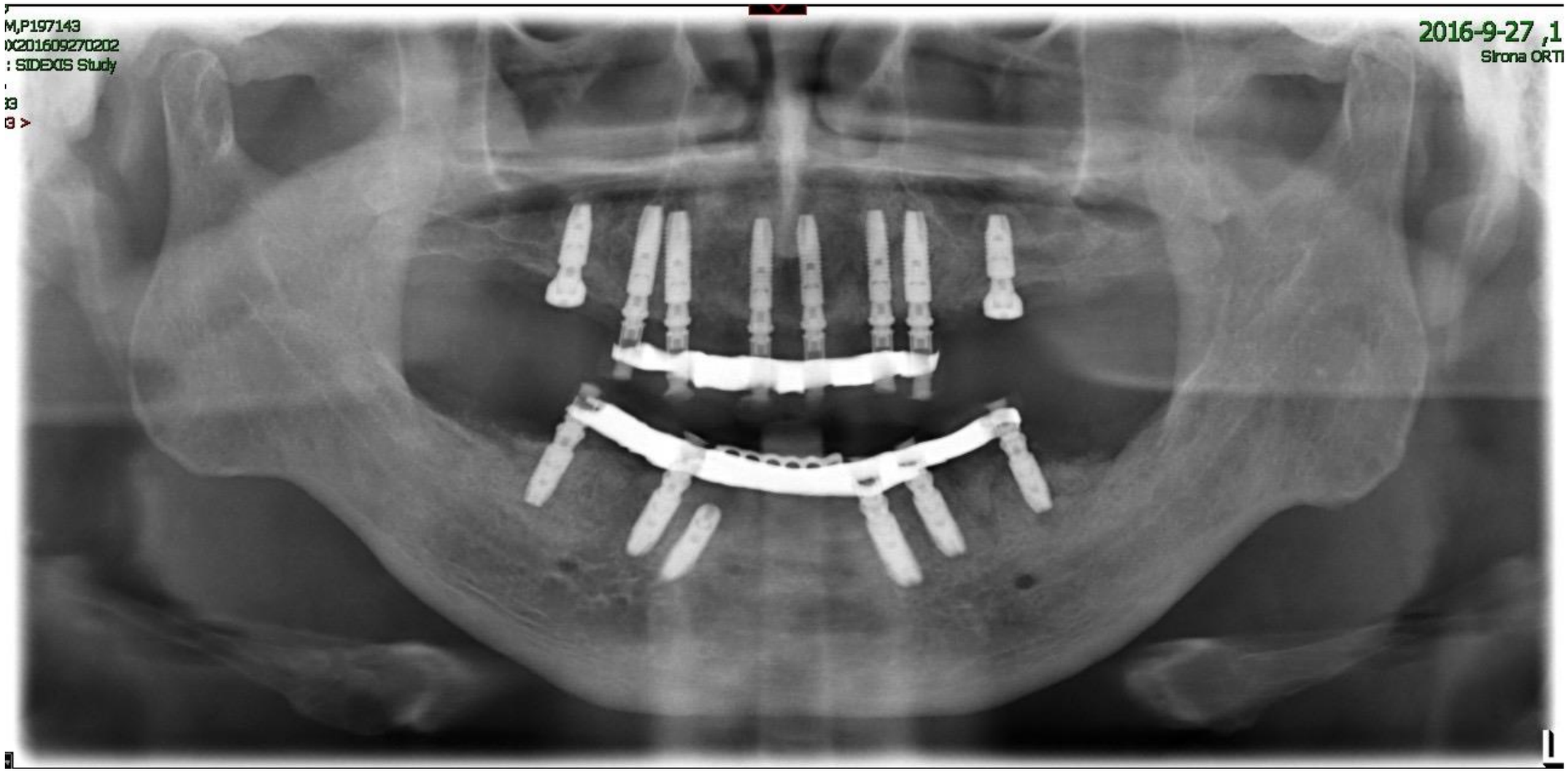
M,P197143
X201609270202
: SIDEXIS Study
2016-9-27 ,1
Sirona ORTI

# 一周后戴牙

# 5个月后复诊

# 5个月后复诊

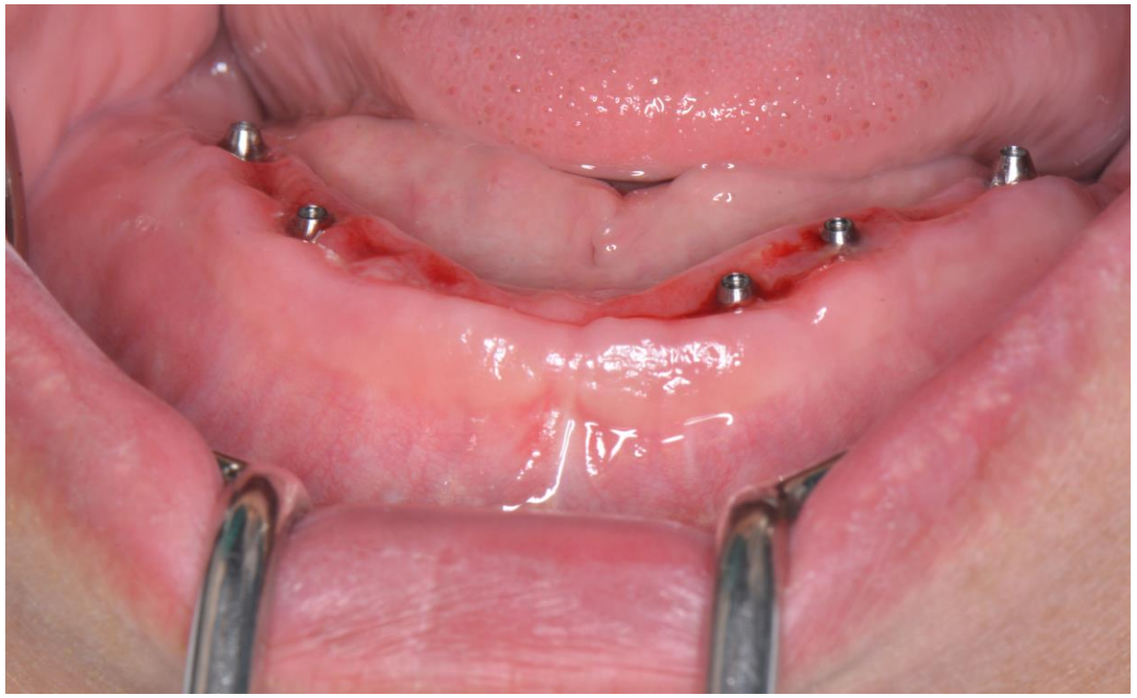

## 临时牙桥体底端塑形

## 塑形前　　塑形后

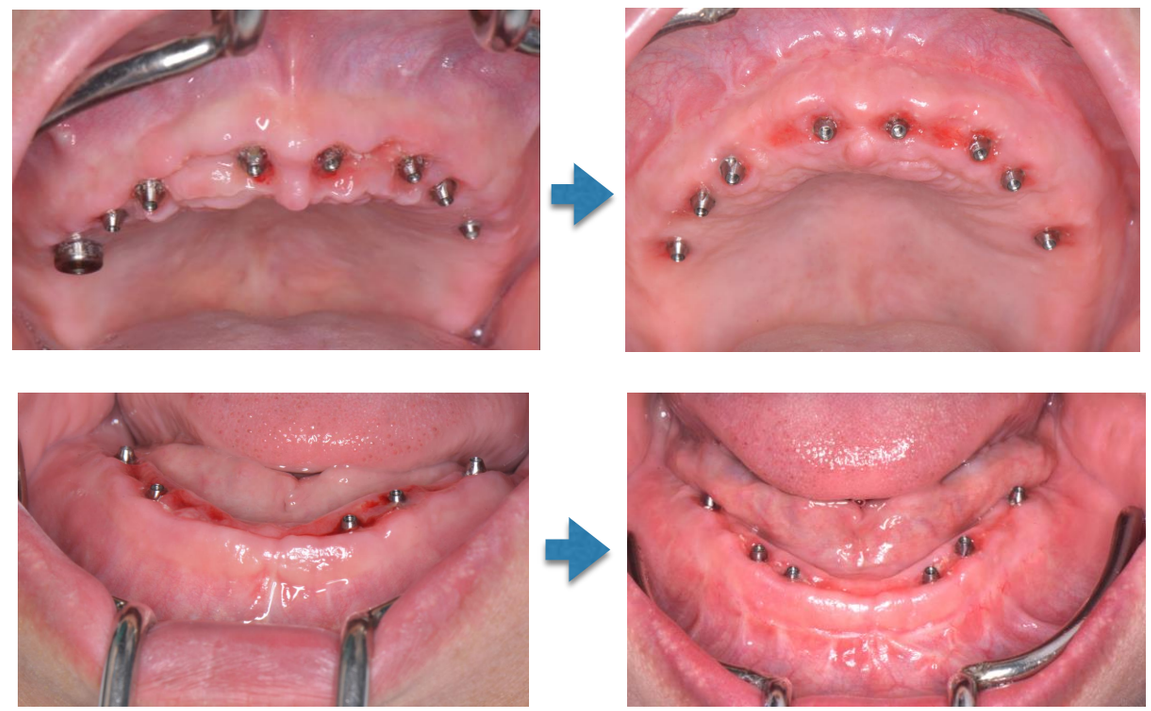

**植体良好的位点，植体周围充足的骨量**

**→ 牙龈塑形**

# 个性化排牙

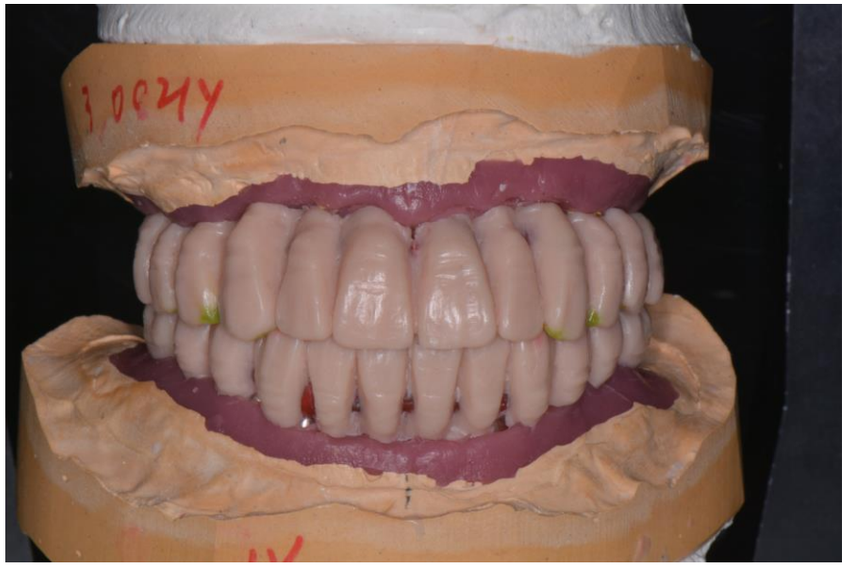

# 完成修复

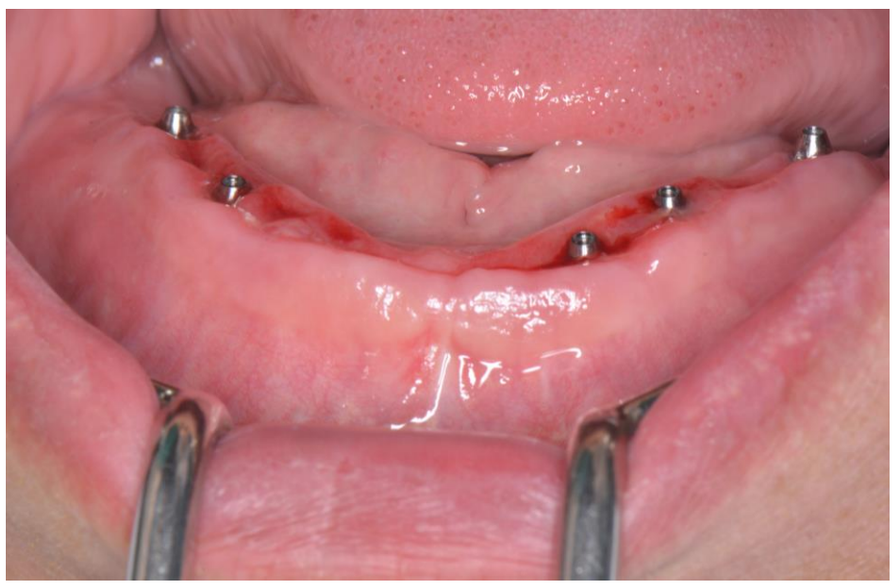

# 完成修复

# 完成修复

月,M,P197143
DX201704250568
明: SIDEXIS Study
E: B
2017-4-25 ,17:58
Sirona ORTHOPH
51%

# 完成修复

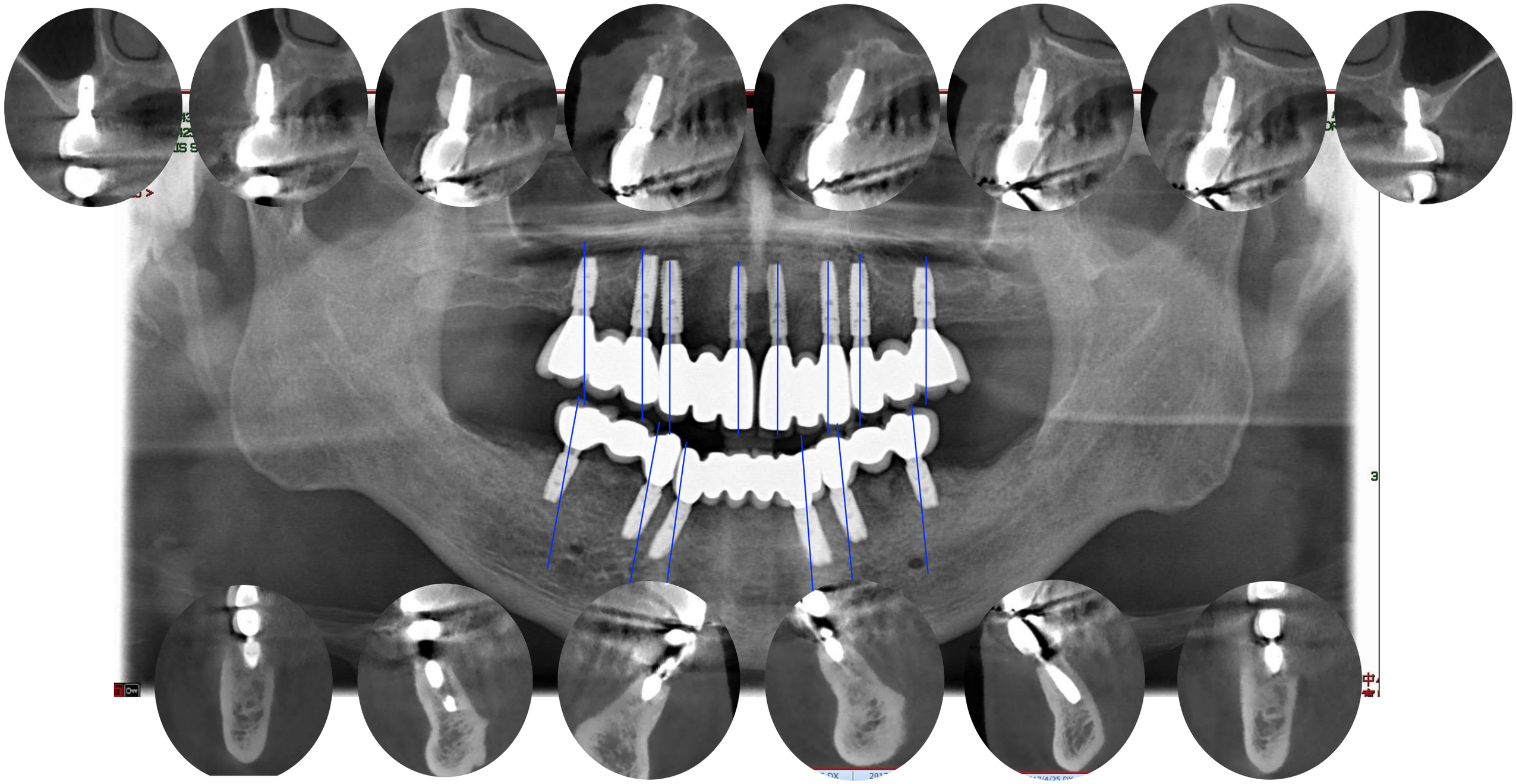

# 随 诊

13个月后复诊

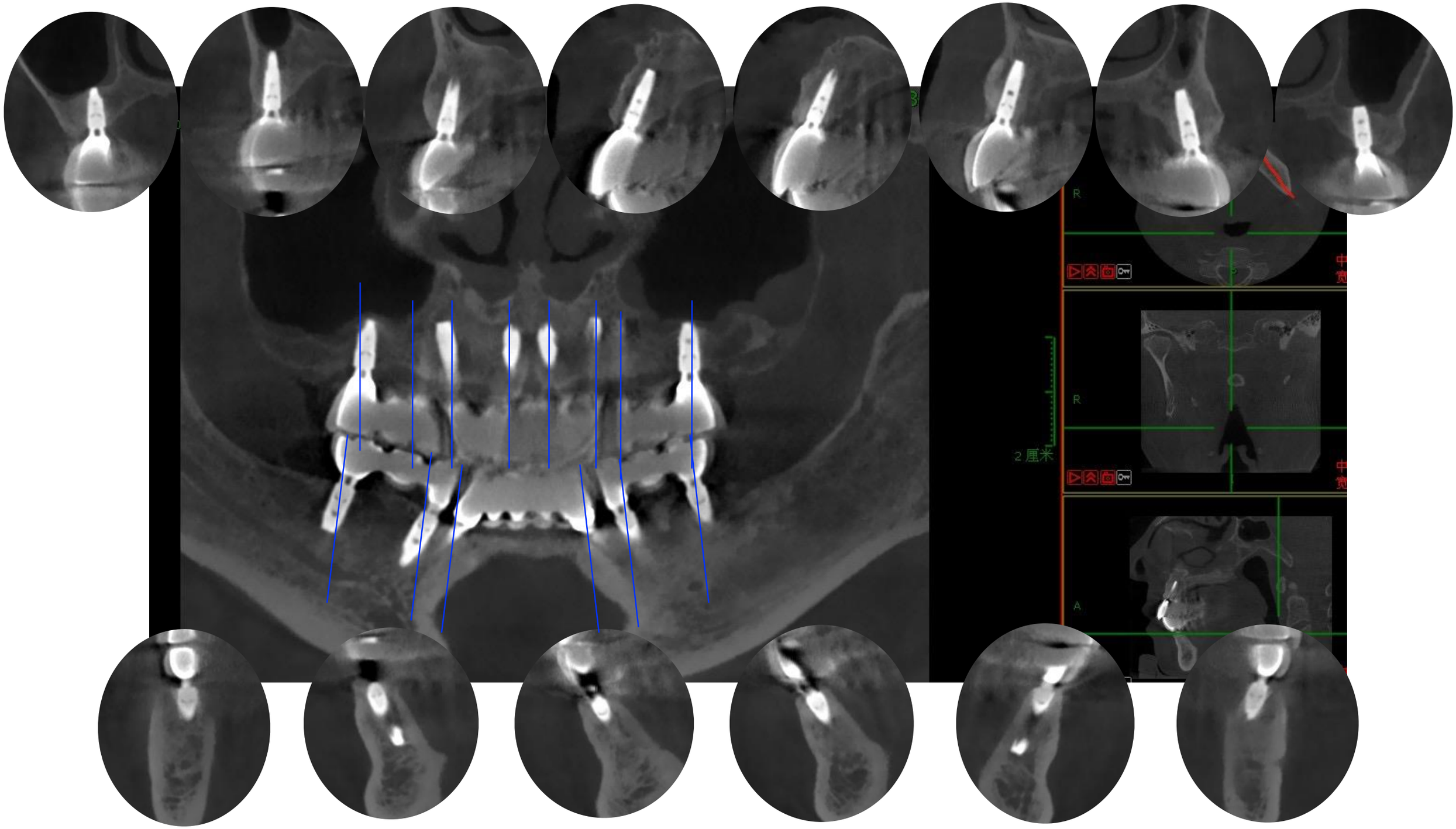
R
2 厘米
R
A

# 小结：

J Periodontol 2014;85:92-102.

Volume 85 • Number 1

Review

## Effects of Currently Available Surgical and Restorative Interventions on Reducing Midfacial Mucosal Recession of Immediately Placed Single-Tooth Implants: A Systematic Review

Guo-Hao Lin,*† Hsun-Liang Chan,† and Hom-Lay Wang†

### DISCUSSION

IIP might be associated with a higher incidence of MR[20] and subsequent poor esthetic appearance, especially for sites with thin soft tissues or wide bony defects on the buccal plate.[20] The underlying mechanism is not fully understood. It is possible that normal socket healing is exacerbated by additional surgical trauma introduced by placing an implant immediately.[75] Additionally, the behavior of buccal plate remodeling is highly unpredictable. It is much more difficult to determine vertical implant level in relation to the alveolar crest in IIP than in late implant placement cases. Finally, there is a tendency for surgical drills and implants to shift to the buccal side, thus increasing the risk of MR.[76] For patients with a high risk for MR, a delayed approach might be preferred. There are cases where IIP might be indicated, and at the same time, a moderate esthetic risk might be encountered. Therefore, possible procedures, including placing implants in a more palatal/lingual position, using platform-switched implants, introducing the flapless approach, using bone grafting materials to fill the horizontal gap between implant and facial plate, adding CTGs, and fabricating immediate fixed provisionalization, should be executed to minimize the amount of MR.

**分析了即刻种植远期软组织退缩的风险，提出规避风险的办法**

**1.将种植体放置在一个更腭/舌的位置**

**2.使用平台切换种植体**

**3.使用植骨材料来填补种植体和颊侧骨板之间的间隙**

**4. 添加CTGs**

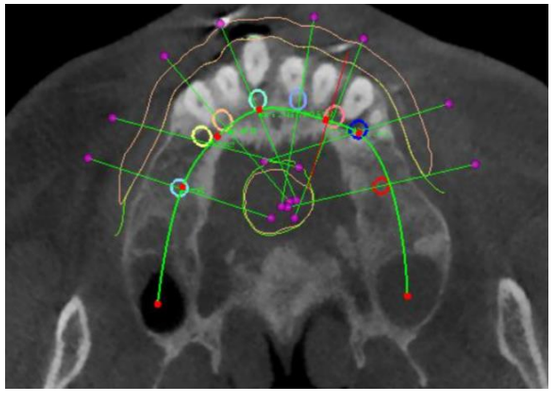

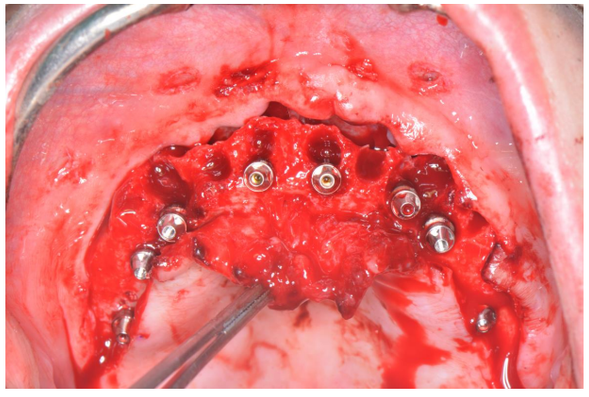

# 小结：

J Periodontol 2014;85:92-102.

Review

Effects of Currently Available Surgical and Restorative Interventions on Reducing Midfacial Mucosal Recession of Immediately Placed Single-Tooth Implants: A Systematic Review

Guo-Hao Lin,*† Hsun-Liang Chan,‡ and Hom-Lay Wang‡

Use of bone grafting materials alters the modeling process of the buccal plate after tooth extraction.[81] Socket augmentation with various types of bone grafts changes the bone quality[82] and reduces the amount of ridge resorption.[83] The effect of bone grafts on soft-tissue alterations is not often

2017

The Efficacy of Immediate Implant Placement in Extraction Sockets for Alveolar Bone Preservation: A Clinical Evaluation Using Three-Dimensional Cone Beam Computerized Tomography and Resonance Frequency Analysis Value

Ali Al Qabbani, DDS,*†‡ Noor Hayati A. Razak, MSc,‡ Sausan Al Kawas, PhD,*1 Suzina Sheikh Abdul Hamid, PhD,‡

In conclusion, the insertion of immediate implants in fresh extraction sockets together with grafting the circumferential gap between the bony socket wall and the implant surface with bovine bone granules was able to preserve a greater amount of alveolar ridge volume when compared with an extraction socket that was left to heal in a conventional way.

Clin. Oral Impl. Res. 00, 2016; 1–9

CLINICAL ORAL IMPLANTS RESEARCH

Mariano Sanz
Jan Lindhe
Jaime Alcaraz
Ignacio Sanz-Sanchez
Denis Cecchinato

The effect of placing a bone replacement graft in the gap at immediately placed implants: a randomized clinical trial

**Conclusions:** In conclusion, the results from this clinical trial demonstrated that placing a DBBM-C bone replacement graft significantly reduced the horizontal bone resorptive changes occurring in the buccal bone after the immediate implantation in fresh extraction sockets.

Maxillofacial Plastic and Reconstructive Surgery (2018) 40:8

Jun et al. Maxillofacial Plastic and Reconstructive Surgery (2018) 40:8
https://doi.org/10.1186/s40902-018-0148-2

Maxillofacial Plastic and Reconstructive Surgery

RESEARCH Open Access

The influence of bone graft procedures on primary stability and bone change of implants placed in fresh extraction sockets

Sang Ho Jun[1†], Chang-Joo Park[2†], Suk-Hyun Hwang[3], Youn Ki Lee[3], Cong Zhou[3], Hyon-Seok Jang[4] and Jae-Jun Ryu[5*]

**Conclusions:** Bone graft procedure is beneficial for increasing the primary stability of immediately placed implants, especially when the ISQ of implants is below 65 and that bone grafts have some effects on peri-implant bone maintenance.

**植骨材料的使用改变了拔牙后颊侧骨板的改建过程**

**即刻种植不同类型的植骨增加了牙槽骨的数量**

**显著降低了即刻种植后颊侧骨板水平骨吸收和骨嵴垂直吸收的程度**

**植骨过程有利于提高即刻种植体的初始稳定性，尤其当种植体的ISQ值较低时更是如此**

# 小结：

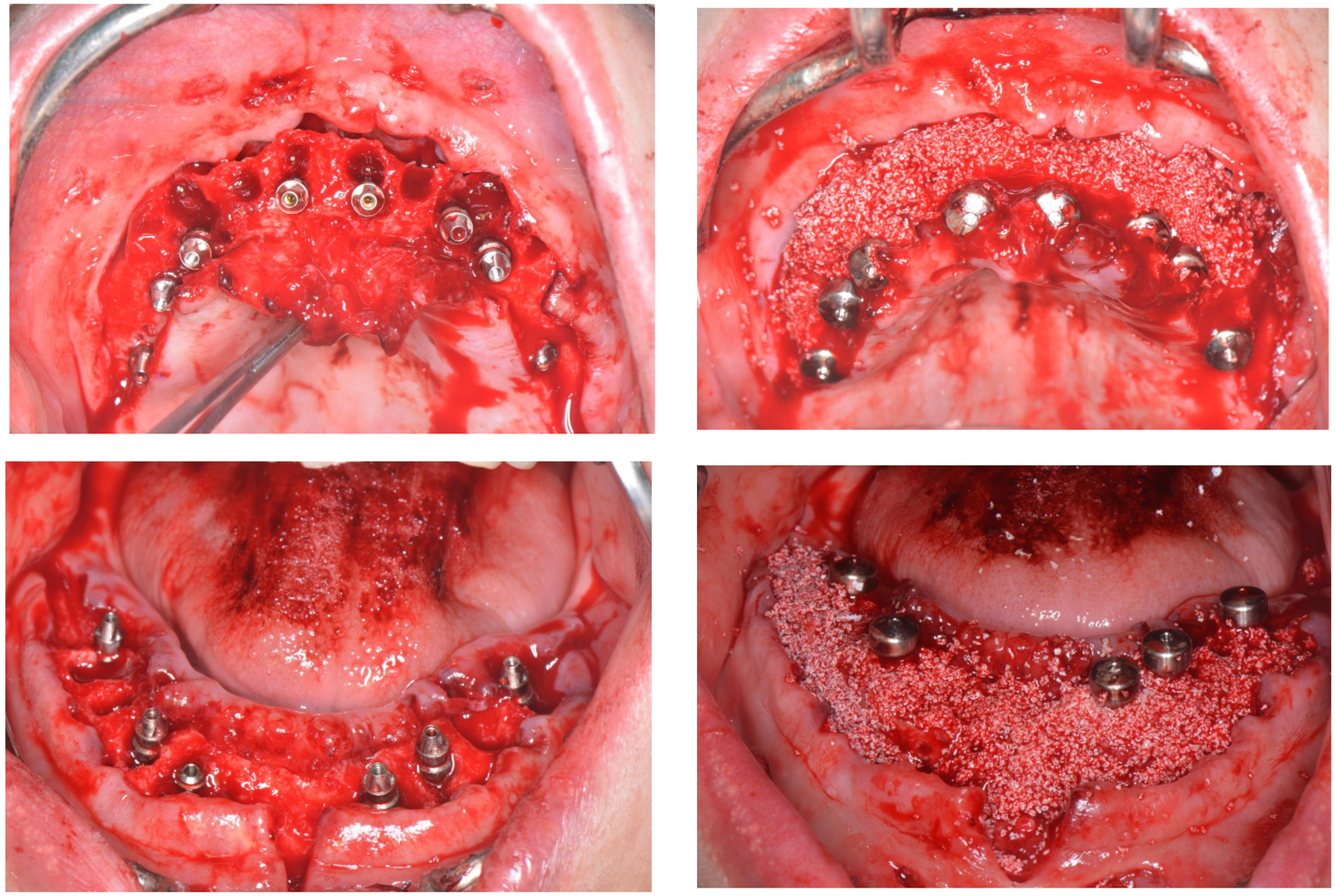

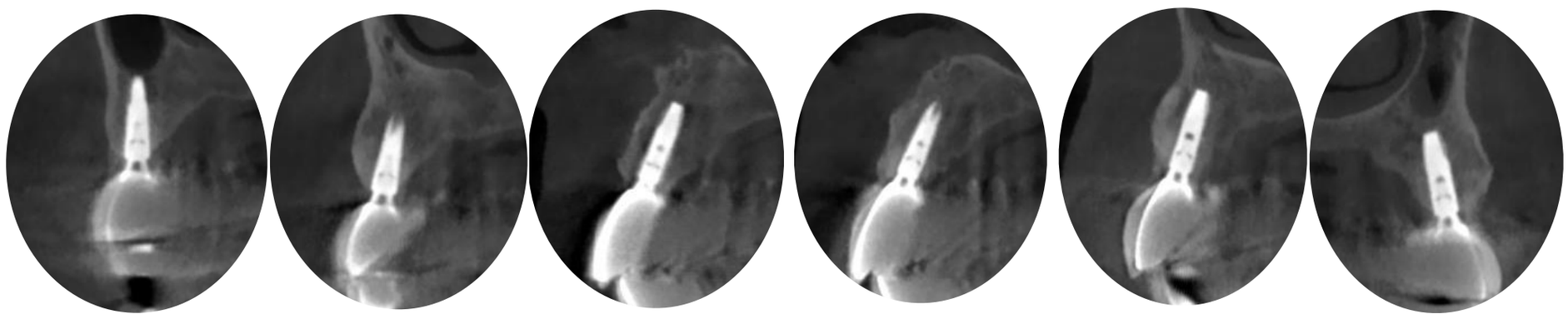

植体良好的位点，适当的植骨

植体周围充足的骨量

# Thank you for your attention!